


SAMPLE TEST QUESTIONS

Step 1



This booklet was updated February 2019.

Copyright © 2019 by the Federation of State Medical Boards of the United States, Inc. (FSMB), and the National Board of Medical Examiners® (NBME®). All rights reserved. Printed in the United States of America. The United States Medical Licensing Examination (USMLE®) is a joint program of the FSMB and the NBME.

CONTENTS

| | |
|--|----|
| USMLE Step 1 Test Question Formats | 3 |
| Introduction to USMLE Step 1 Sample Test Questions | 4 |
| Normal Laboratory Values | 5 |
| USMLE Step 1 Sample Test Questions..... | 7 |
| Answer Form for USMLE Step 1 Sample Test Questions..... | 44 |
| Answer Key for USMLE Step 1 Sample Test Questions..... | 45 |

Single-Item Questions

A single patient-centered vignette is associated with one question followed by four or more response options. The response options are lettered (A, B, C, D, E). A portion of the questions require interpretation of graphic or pictorial materials. You are required to select the best answer to the question. Other options may be partially correct, but there is only ONE BEST answer. This is the traditional, most frequently used multiple-choice question format on the examination.

Strategies for Answering Single One-Best-Answer Test Questions

The following are strategies for answering one-best-answer items:

- Read each patient vignette and question carefully. It is important to understand what is being asked.
- Try to generate an answer and then look for it in the response option list.
- Alternatively, read each response option carefully, eliminating those that are clearly incorrect.
- Of the remaining options, select the one that is most correct.
- If unsure about an answer, it is better to guess since unanswered questions are automatically counted as wrong answers.

Example Item

A 32-year-old woman with type 1 diabetes mellitus has had progressive renal failure over the past 2 years. She has not yet started dialysis. Examination shows no abnormalities. Her hemoglobin concentration is 9 g/dL, hematocrit is 28%, and mean corpuscular volume is 94 μm^3 . A blood smear shows normochromic, normocytic cells. Which of the following is the most likely cause?

- | | |
|-----------------------------------|--------------------------------|
| (A) Acute blood loss | (F) Microangiopathic hemolysis |
| (B) Chronic lymphocytic leukemia | (G) Polycythemia vera |
| (C) Erythrocyte enzyme deficiency | (H) Sickle cell disease |
| (D) Erythropoietin deficiency | (I) Sideroblastic anemia |
| (E) Immuno-hemolysis | (J) β -Thalassemia trait |

(Answer: D)

NOTE: Some item types that appear on the Step 1 examination are NOT depicted in the sample items provided in this booklet, eg, items with multimedia features, such as audio. Also, when additional item formats are added to the exam, notice will be provided at the USMLE website: <http://www.usmle.org>. You must monitor the website to stay informed about the types of items that occur in the exam, and you must practice with the downloadable sample test items available on the USMLE website to be fully prepared for the examination.

INTRODUCTION TO USMLE STEP 1 SAMPLE TEST QUESTIONS

The following pages include 117 sample test questions. Most of these questions are the same as those you can install on your computer from the USMLE website. Please note that reviewing the sample questions as they appear on pages 7-43 is not a substitute for practicing with the test software. You should download and run the Step 1 tutorial and practice test items that are provided on the USMLE website well before your test date. The sample materials available on the USMLE website include additional items and item formats that do not appear in this booklet, such as items with associated audio or video findings. You should become familiar with all item formats that will be used in the actual examination.

Although the sample questions exemplify content on the Step 1 examination overall, they may not reflect the content coverage on individual examinations. In the actual examination, questions will be presented in random order; they will not be grouped according to specific content. The questions will be presented one at a time in a format designed for easy on-screen reading, including use of the Normal Laboratory Values table (included here on pages 5 and 6) and some pictorials. Photographs, charts, and x-rays in this booklet are not of the same quality as the pictorials used in the actual examination. In addition, you will be able to adjust the brightness and contrast of pictorials on the computer screen.

To take the following sample test questions as they would be timed in the actual examination, you should allow a maximum of 1 hour for each 40-item block, and a maximum of 55 minutes, 30 seconds, for the 37-item block, for a total of 2 hours, 55 minutes, 30 seconds. Please note that the third block has 37 items instead of 40 because the multimedia items have been removed, and the recommended time to complete the block has been adjusted accordingly. Please be aware that most examinees perceive the time pressure to be greater during an actual examination. All examinees are strongly encouraged to practice with the downloadable version to become familiar with all item formats and exam timing. An answer form for recording answers is provided on page 44. An answer key is provided on page 45. In the actual examination, answers will be selected on the screen; no answer form will be provided.

LABORATORY VALUES

| | <u>REFERENCE RANGE</u> | <u>SI REFERENCE INTERVALS</u> |
|---|--|------------------------------------|
| BLOOD, PLASMA, SERUM | | |
| Alanine aminotransferase (ALT), serum..... | 8-20 U/L | 8-20 U/L |
| Amylase, serum..... | 25-125 U/L..... | 25-125 U/L |
| Aspartate aminotransferase (AST), serum | 8-20 U/L..... | 8-20 U/L |
| Bilirubin, serum (adult) Total // Direct | 0.1-1.0 mg/dL // 0.0-0.3 mg/dL | 2-17 µmol/L // 0-5 µmol/L |
| Calcium, serum (Ca ²⁺)..... | 8.4-10.2 mg/dL..... | 2.1-2.8 mmol/L |
| Cholesterol, serum | Rec:<200 mg/dL | <5.2 mmol/L |
| Cortisol, serum..... | 0800 h: 5-23 µg/dL // 1600 h: 3-15 µg/dL | 138-635 nmol/L // 82-413 nmol/L |
| | 2000 h: ≤ 50% of 0800 h | Fraction of 0800 h: ≤ 0.50 |
| Creatine kinase, serum | Male: 25-90 U/L | 25-90 U/L |
| | Female: 10-70 U/L | 10-70 U/L |
| Creatinine, serum..... | 0.6-1.2 mg/dL | 53-106 µmol/L |
| Electrolytes, serum | | |
| Sodium (Na ⁺) | 136-145 mEq/L..... | 136-145 mmol/L |
| Potassium (K ⁺)..... | 3.5-5.0 mEq/L | 3.5-5.0 mmol/L |
| Chloride (Cl ⁻)..... | 95-105 mEq/L | 95-105 mmol/L |
| Bicarbonate (HCO ₃ ⁻) | 22-28 mEq/L | 22-28 mmol/L |
| Magnesium (Mg ²⁺)..... | 1.5-2.0 mEq/L | 0.75-1.0 mmol/L |
| Estriol, total, serum (in pregnancy) | | |
| 24-28 wks // 32-36 wks | 30-170 ng/mL // 60-280 ng/mL | 104-590 nmol/L // 208-970 nmol/L |
| 28-32 wks // 36-40 wks | 40-220 ng/mL // 80-350 ng/mL | 140-760 nmol/L // 280-1210 nmol/L |
| Ferritin, serum..... | Male: 15-200 ng/mL | 15-200 µg/L |
| | Female: 12-150 ng/mL | 12-150 µg/L |
| Follicle-stimulating hormone, serum/plasma | | |
| | Male: 4-25 mIU/mL | 4-25 U/L |
| | Female: premenopause 4-30 mIU/mL | 4-30 U/L |
| | midcycle peak 10-90 mIU/mL | 10-90 U/L |
| | postmenopause 40-250 mIU/mL | 40-250 U/L |
| Gases, arterial blood (room air) | | |
| pH | 7.35-7.45 | [H ⁺] 36-44 nmol/L |
| PCO ₂ | 33-45 mm Hg | 4.4-5.9 kPa |
| PO ₂ | 75-105 mm Hg | 10.0-14.0 kPa |
| Glucose, serum..... | | |
| | Fasting: 70-110 mg/dL | 3.8-6.1 mmol/L |
| | 2-h postprandial: < 120 mg/dL | < 6.6 mmol/L |
| Growth hormone - arginine stimulation | | |
| | Fasting: < 5 ng/mL | < 5 µg/L |
| | provocative stimuli: > 7 ng/mL | > 7 µg/L |
| Immunoglobulins, serum | | |
| IgA | 76-390 mg/dL..... | 0.76-3.90 g/L |
| IgE | 0-380 IU/mL..... | 0-380 kIU/L |
| IgG | 650-1500 mg/dL | 6.5-15 g/L |
| IgM | 40-345 mg/dL | 0.4-3.45 g/L |
| Iron | 50-170 µg/dL | 9-30 µmol/L |
| Lactate dehydrogenase, serum | 45-90 U/L..... | 45-90 U/L |
| Luteinizing hormone, serum/plasma | | |
| | Male: 6-23 mIU/mL | 6-23 U/L |
| | Female: follicular phase 5-30 mIU/mL | 5-30 U/L |
| | midcycle 75-150 mIU/mL | 75-150 U/L |
| | postmenopause 30-200 mIU/mL | 30-200 U/L |
| Osmolality, serum | 275-295 mOsmol/kg H ₂ O..... | 275-295 mOsmol/kg H ₂ O |
| Parathyroid hormone, serum, N-terminal | 230-630 pg/mL | 230-630 ng/L |
| Phosphatase (alkaline), serum (p-NPP at 30°C) | 20-70 U/L | 20-70 U/L |
| Phosphorus (inorganic), serum..... | 3.0-4.5 mg/dL | 1.0-1.5 mmol/L |
| Prolactin, serum (hPRL) | < 20 ng/mL | < 20 µg/L |
| Proteins, serum | | |
| Total (recumbent) | 6.0-7.8 g/dL | 60-78 g/L |
| Albumin | 3.5-5.5 g/dL..... | 35-55 g/L |
| Globulin | 2.3-3.5 g/dL..... | 23-35 g/L |
| Thyroid-stimulating hormone, serum or plasma..... | 0.5-5.0 µU/mL | 0.5-5.0 mU/L |
| Thyroidal iodine (¹²³ I) uptake..... | 8%-30% of administered dose/24 h | 0.08-0.30/24 h |
| Thyroxine (T ₄), serum..... | 5-12 µg/dL | 64-155 nmol/L |
| Triglycerides, serum..... | 35-160 mg/dL..... | 0.4-1.81 mmol/L |
| Triiodothyronine (T ₃), serum (RIA) | 115-190 ng/dL | 1.8-2.9 nmol/L |
| Triiodothyronine (T ₃) resin uptake..... | 25%-35% | 0.25-0.35 |
| Urea nitrogen, serum | 7-18 mg/dL | 1.2-3.0 mmol/L |
| Uric acid, serum..... | 3.0-8.2 mg/dL | 0.18-0.48 mmol/L |

LABORATORY VALUES (continued)

| | REFERENCE RANGE | SI REFERENCE INTERVALS |
|---|---|-----------------------------------|
| BODY MASS INDEX (BMI) | | |
| Body mass index | Adult: 19-25 kg/m ² | |
| CEREBROSPINAL FLUID | | |
| Cell count | 0-5/mm ³ | 0-5 x 10 ⁶ /L |
| Chloride | 118-132 mEq/L | 118-132 mmol/L |
| Gamma globulin | 3%-12% total proteins | 0.03-0.12 |
| Glucose | 40-70 mg/dL | 2.2-3.9 mmol/L |
| Pressure | 70-180 mm H ₂ O | 70-180 mm H ₂ O |
| Proteins, total | <40 mg/dL | <0.40 g/L |
| HEMATOLOGIC | | |
| Bleeding time (template) | 2-7 minutes | 2-7 minutes |
| Erythrocyte count | Male: 4.3-5.9 million/mm ³ | 4.3-5.9 x 10 ¹² /L |
| | Female: 3.5-5.5 million/mm ³ | 3.5-5.5 x 10 ¹² /L |
| Erythrocyte sedimentation rate (Westergren) | Male: 0-15 mm/h | 0-15 mm/h |
| | Female: 0-20 mm/h | 0-20 mm/h |
| Hematocrit | Male: 41%-53% | 0.41-0.53 |
| | Female: 36%-46% | 0.36-0.46 |
| Hemoglobin A _{1c} | ≤ 6% | ≤ 0.06 |
| Hemoglobin, blood | Male: 13.5-17.5 g/dL | 2.09-2.71 mmol/L |
| | Female: 12.0-16.0 g/dL | 1.86-2.48 mmol/L |
| Hemoglobin, plasma | 1-4 mg/dL | 0.16-0.62 mmol/L |
| Leukocyte count and differential | | |
| Leukocyte count | 4500-11,000/mm ³ | 4.5-11.0 x 10 ⁹ /L |
| Segmented neutrophils | 54%-62% | 0.54-0.62 |
| Bands | 3%-5% | 0.03-0.05 |
| Eosinophils | 1%-3% | 0.01-0.03 |
| Basophils | 0%-0.75% | 0-0.0075 |
| Lymphocytes | 25%-33% | 0.25-0.33 |
| Monocytes | 3%-7% | 0.03-0.07 |
| Mean corpuscular hemoglobin | 25.4-34.6 pg/cell | 0.39-0.54 fmol/cell |
| Mean corpuscular hemoglobin concentration | 31%-36% Hb/cell | 4.81-5.58 mmol Hb/L |
| Mean corpuscular volume | 80-100 µm ³ | 80-100 fL |
| Partial thromboplastin time (activated) | 25-40 seconds | 25-40 seconds |
| Platelet count | 150,000-400,000/mm ³ | 150-400 x 10 ⁹ /L |
| Prothrombin time | 11-15 seconds | 11-15 seconds |
| Reticulocyte count | 0.5%-1.5% | 0.005-0.015 |
| Thrombin time | <2 seconds deviation from control | <2 seconds deviation from control |
| Volume | | |
| Plasma | Male: 25-43 mL/kg | 0.025-0.043 L/kg |
| | Female: 28-45 mL/kg | 0.028-0.045 L/kg |
| Red cell | Male: 20-36 mL/kg | 0.020-0.036 L/kg |
| | Female: 19-31 mL/kg | 0.019-0.031 L/kg |
| SWEAT | | |
| Chloride | 0-35 mmol/L | 0-35 mmol/L |
| URINE | | |
| Calcium | 100-300 mg/24 h | 2.5-7.5 mmol/24 h |
| Chloride | Varies with intake | Varies with intake |
| Creatinine clearance | Male: 97-137 mL/min | |
| | Female: 88-128 mL/min | |
| Estriol, total (in pregnancy) | | |
| 30 wks | 6-18 mg/24 h | 21-62 µmol/24 h |
| 35 wks | 9-28 mg/24 h | 31-97 µmol/24 h |
| 40 wks | 13-42 mg/24 h | 45-146 µmol/24 h |
| 17-Hydroxycorticosteroids | Male: 3.0-10.0 mg/24 h | 8.2-27.6 µmol/24 h |
| | Female: 2.0-8.0 mg/24 h | 5.5-22.0 µmol/24 h |
| 17-Ketosteroids, total | Male: 8-20 mg/24 h | 28-70 µmol/24 h |
| | Female: 6-15 mg/24 h | 21-52 µmol/24 h |
| Osmolality | 50-1400 mOsm/kg H ₂ O | |
| Oxalate | 8-40 µg/mL | 90-445 µmol/L |
| Potassium | Varies with diet | Varies with diet |
| Proteins, total | <150 mg/24 h | <0.15 g/24 h |
| Sodium | Varies with diet | Varies with diet |
| Uric acid | Varies with diet | Varies with diet |

USMLE STEP 1 SAMPLE TEST QUESTIONS

BLOCK 1, ITEMS 1-40

1. A 28-year-old man comes to the physician because of a 1-year history of pain with urination that has increased in severity during the past month. He also has had episodes of blood in his urine during the past 5 years. He lived in sub-Saharan Africa until he came to the USA 6 months ago for graduate school. His temperature is 38°C (100.4°F), pulse is 80/min, respirations are 16/min, and blood pressure is 110/84 mm Hg. Physical examination shows suprapubic tenderness. Laboratory studies show:

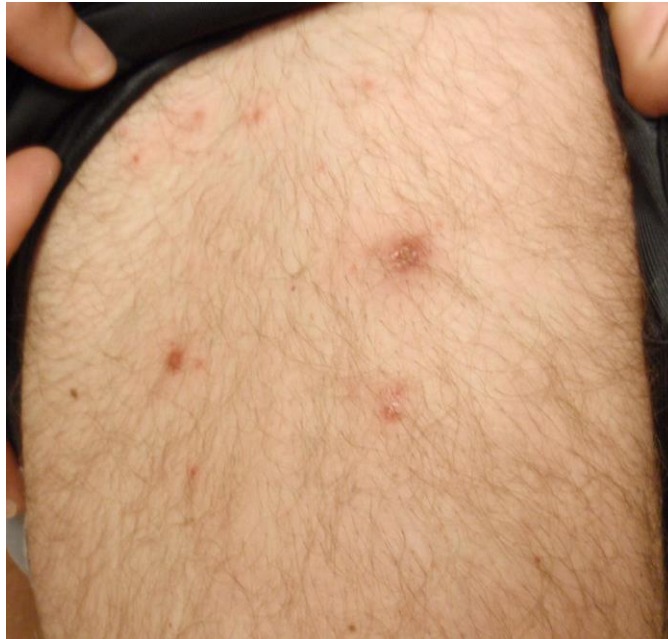| | |
|-----------------------|------------------------|
| Hemoglobin | 12.3 g/dL |
| Hematocrit | 37% |
| Leukocyte count | 13,400/mm ³ |
| Segmented neutrophils | 65% |
| Bands | 5% |
| Eosinophils | 5% |
| Lymphocytes | 22% |
| Monocytes | 3% |
| Serum | |
| Urea nitrogen | 75 mg/dL |
| Creatinine | 3.8 mg/dL |
| Urine | |
| Blood | 3+ |
| RBC | 200/hpf |
| WBC | 100/hpf |
| RBC casts | absent |
| WBC casts | absent |

Imaging studies show bilateral hydroureter and hydronephrosis and foci of calcification in the region of the bladder. A biopsy specimen of the bladder shows marked chronic inflammation with fibrosis and scattered granulomas. Which of the following best explains the biopsy findings?

- (A) Exposure to a chemical toxin
- (B) Interstitial cystitis
- (C) Malacoplakia
- (D) Schistosomiasis
- (E) Vesicoureteral reflux

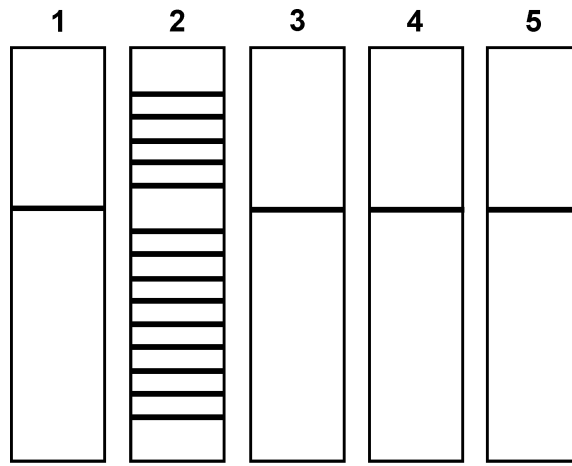
-
2. A 14-year-old boy is brought to the emergency department after being hit with a baseball bat on the lateral side of his leg immediately below the knee. He is unable to dorsiflex his foot. Which of the following nerves is most likely injured?

- (A) Common fibular (peroneal)
- (B) Femoral
- (C) Obturator
- (D) Sural
- (E) Tibial



3. A 24-year-old man comes to the office because of a 2-day history of a red, itchy rash on his buttocks and legs. Four days ago, he returned from a cruise to the Caribbean, during which he swam in the ship's pool and used the hot tub. He appears well. His vital signs are within normal limits. Physical examination shows the findings in the photograph. The infectious agent causing these findings most likely began to proliferate in which of the following locations?
- (A) Apocrine gland
 - (B) Dermis
 - (C) Eccrine gland
 - (D) Hair follicle
 - (E) Sebaceous gland
-
4. A 14-year-old girl is brought to the physician after her mother learned that she began having sexual intercourse with various partners 1 month ago. She does not use condoms or other contraception. The mother is concerned about her behavior. The patient's parents separated 3 months ago. She had been an honor student and excelled in sports and leadership positions at school before the separation. Since the separation, however, she has become sullen, defiant, and rebellious. She has begun smoking cigarettes, disobeying her curfew, and being truant from school. This patient is most likely using which of the following defense mechanisms?
- (A) Acting out
 - (B) Displacement
 - (C) Projection
 - (D) Reaction formation
 - (E) Sublimation

5. A 24-year-old woman comes to the physician for a follow-up examination. One week ago, she was treated in the emergency department after she accidentally spilled hot grease on her left leg while working at a fast-food restaurant. Examination of the left lower extremity shows a 7-cm, pink, soft, granular, edematous wound. The formation of this tissue was most likely caused by increased activity of which of the following?
- (A) Complement C3b
 - (B) Glycosylation-dependent cell adhesion molecule-1
 - (C) P-selectin
 - (D) Stromelysin
 - (E) Vascular endothelial growth factor
6. A 63-year-old woman comes to the physician 1 day after the sudden onset of pain and swelling of her right knee. She has had no injury. Her medications include occasional ibuprofen for mild osteoarthritis of both knees. Her temperature is 37°C (98.6°F), pulse is 97/min, respirations are 19/min, and blood pressure is 129/79 mm Hg. Examination of the right knee shows warmth, erythema, and effusion. Exquisite tenderness is produced with minimal range-of-motion testing. Examination of synovial fluid obtained via joint aspiration shows that it is clear, with positively birefringent rhomboids observed under polarized light microscopy. Deposition of which of the following substances is the most likely cause of these findings?
- (A) Ammonium urate
 - (B) Calcium oxalate
 - (C) Calcium pyrophosphate
 - (D) Calcium urate
 - (E) Sodium urate
7. A 55-year-old woman with small cell carcinoma of the lung is admitted to the hospital to undergo chemotherapy. Six days after treatment is started, she develops a temperature of 38°C (100.4°F). Physical examination shows no other abnormalities. Laboratory studies show a leukocyte count of $100/\text{mm}^3$ (5% segmented neutrophils and 95% lymphocytes). Which of the following is the most appropriate pharmacotherapy to increase this patient's leukocyte count?
- (A) Darbepoetin
 - (B) Dexamethasone
 - (C) Filgrastim
 - (D) Interferon alfa
 - (E) Interleukin-2 (IL-2)
 - (F) Leucovorin
8. A 37-year-old woman with right lower extremity edema is evaluated because of the sudden onset of shortness of breath and pleuritic chest pain. A diagnosis of pulmonary embolism is made. Which of the following signs, if present on physical examination, would be the most specific indicator of pulmonary arterial hypertension in this patient?
- (A) Increased jugular venous pressure
 - (B) P₂ louder than A₂
 - (C) Peripheral edema
 - (D) Presence of an S₃
 - (E) Pulmonary crackles



Lane 1: Liver
 Lane 2: Bone Marrow
 Lane 3: Kidney
 Lane 4: Cerebellum
 Lane 5: Pancreas

9. During an experiment, a Southern blot analysis is done by digesting DNA samples with a single restriction endonuclease, separating the digestion products by gel electrophoresis, and transferring them to a filter. The investigator probes the filter by exposing it to a cDNA clone that encodes a single immunoglobulin-constant region. The figure shows the resulting pattern with DNA samples isolated from different organs. Assuming there were no technical errors, the Southern blot analysis results demonstrate which of the following processes?
- (A) Affinity maturation
 - (B) Apoptosis
 - (C) Gene rearrangement
 - (D) RNA splicing
 - (E) Somatic hypermutation
-
10. During a clinical study examining the effects of exercise, men between the ages of 20 and 30 years are evaluated during a 15-minute session on a treadmill. The average pulse for the last 2 minutes of the session is 175/min. During the last minute of exercise, various measurements are taken. Compared with the measurement before the session, which of the following is most likely to be decreased?
- (A) Cardiac output
 - (B) Oxygen consumption
 - (C) Pulse pressure
 - (D) Stroke volume
 - (E) Systolic blood pressure
 - (F) Total peripheral resistance

11. A 26-year-old man is brought to the emergency department by ambulance 30 minutes after being shot in the leg. He is unconscious and appears markedly pale. His pulse is 120/min, respirations are 16/min, and blood pressure is 80/60 mm Hg. Compared with a healthy adult, which of the following findings is most likely in this patient?

| | Arterial Baroreceptor Firing Rate | Systemic Vascular Resistance | Pulmonary Vascular Resistance | Systemic Capillary Fluid Transfer |
|-----|--------------------------------------|---------------------------------|----------------------------------|--------------------------------------|
| (A) | ↑ | ↑ | ↑ | filtration |
| (B) | ↑ | ↓ | ↑ | absorption |
| (C) | ↑ | ↓ | ↓ | filtration |
| (D) | ↓ | ↑ | ↑ | absorption |
| (E) | ↓ | ↑ | ↓ | filtration |
| (F) | ↓ | ↓ | ↓ | absorption |

12. A 17-year-old boy is brought to the emergency department 30 minutes after being found with a "blank stare" and flat facial expression at a party. His pulse is 72/min, and blood pressure is 104/68 mm Hg. He is sitting upright and appears catatonic. Physical examination shows rigidity. During the examination, he becomes hostile and attempts to assault the physician. This patient most likely ingested which of the following drugs?

- (A) Cocaine
- (B) Diazepam
- (C) Methamphetamine
- (D) Oxycodone
- (E) PCP (phencyclidine)

13. A 26-year-old woman is brought to the emergency department because of an 8-hour history of severe back and abdominal pain and mild but persistent vaginal bleeding. Ultrasonography of the abdomen shows a 2-cm ectopic pregnancy in the ampulla. The ampulla has ruptured into the surrounding tissue. Fluid from this rupture will most likely be found in which of the following locations?

- (A) Lesser peritoneal cavity
- (B) Mesometrium
- (C) Pouch of Douglas
- (D) Uterine cavity
- (E) Vagina

14. A 14-year-old girl has had nausea, intermittent diarrhea, and a 2.2-kg (5-lb) weight loss over the past 4 weeks. Examination shows a migrating serpiginous pruritic perianal rash. Her leukocyte count is $8000/\text{mm}^3$ with 20% eosinophils. Which of the following tests is most likely to yield an accurate diagnosis?

- (A) Blood smear
- (B) Bone marrow biopsy
- (C) KOH preparation
- (D) Microscopic examination of the stool
- (E) Skin snip

15. A 40-year-old woman comes to the physician because of a 6-month history of increased facial hair growth. Her last menstrual period was 4 months ago. She is 165 cm (5 ft 5 in) tall and weighs 70 kg (154 lb); BMI is 26 kg/m^2 . Her pulse is 80/min, and blood pressure is 130/82 mm Hg. Physical examination shows temporal balding and coarse dark hair on the upper lip and chin. Pelvic examination shows clitoral enlargement. Her serum testosterone concentration is increased. Serum concentrations of androstenedione, dehydroepiandrosterone, and urinary 17-ketosteroids are within the reference ranges. Ultrasonography of the pelvis shows a 12-cm ovarian mass. Which of the following best describes this mass?
- (A) Granulosa tumor
 - (B) Ovarian carcinoid
 - (C) Sertoli-Leydig tumor
 - (D) Teratoma
 - (E) Thecoma
16. A 45-year-old woman with systemic sclerosis (scleroderma) comes to the physician because of a 3-week history of progressive shortness of breath and nonproductive cough. Her temperature is 36.9°C (98.4°F), pulse is 82/min, respirations are 20/min, and blood pressure is 136/85 mm Hg. Crackles are heard in both lower lung fields. Pulmonary function tests show total lung capacity is 80% of predicted, and diffusing capacity for carbon monoxide, corrected for alveolar volume, is 65% of predicted. Histologic examination of a lung biopsy specimen is most likely to show which of the following findings?
- (A) Diffuse interstitial fibrosis
 - (B) Intra-alveolar exudates
 - (C) Multiple thromboemboli
 - (D) Necrotizing vasculitis
 - (E) Non-necrotizing interstitial granulomas
17. A new blood test to detect prostate cancer is evaluated in 300 male volunteers. A needle biopsy of the prostate gland is done on all men with serum prostate-specific antigen concentrations greater than 5 ng/mL ($N < 4$). One hundred men undergo biopsy procedures; 90 are found to have prostate cancer, and five are found to have chronic prostatitis. Which of the following is necessary to calculate the sensitivity of this test?
- (A) Incidence of chronic prostatitis in the general population
 - (B) Number of men with test results greater than 5 ng/mL and a normal biopsy specimen
 - (C) Prevalence of chronic prostatitis in the general population
 - (D) Prostate biopsies of men with test results equal to or below 5 ng/mL
18. A 62-year-old woman comes to the physician because of low back pain for 1 week. Menopause occurred 10 years ago. Physical examination shows localized tenderness over the lumbar spine after movement. X-rays of the spine show a compression fracture of L1-2. A DEXA scan shows decreased bone mineral density. Serum calcium and phosphorus concentrations and serum alkaline phosphatase activity are within the reference ranges. A bisphosphonate drug is prescribed. The expected beneficial effect of this drug is most likely due to which of the following actions?
- (A) Decreased insulin-like growth factor-1 concentration
 - (B) Decreased osteoclast activity
 - (C) Decreased osteoprotegerin production
 - (D) Increased 1,25-dihydroxycholecalciferol concentration
 - (E) Increased osteoblast activity
 - (F) Increased receptor activator of NF- κ B ligand (RANKL) production

19. A 26-year-old woman is brought to the emergency department 3 hours after ingesting approximately 50 tablets of aspirin in a suicide attempt. She is nauseated, confused, and sleepy. Her pulse is 130/min, respirations are 30/min, and blood pressure is 100/60 mm Hg. Which of the following sets of laboratory values is most likely on evaluation of blood obtained before treatment?

| | Serum | Arterial Blood | |
|-----|------------------------------------|-----------------------|------------------------|
| | HCO₃⁻ | pH | Pco₂ |
| (A) | ↑ | ↓ | ↑ |
| (B) | ↓ | ↓ | ↓ |
| (C) | ↑ | ↑ | ↓ |
| (D) | ↓ | ↓ | ↑ |
| (E) | ↑ | ↑ | ↑ |

20. An investigator is studying the incidence of the common cold among medical students at various time points during the school year. Results show an increased incidence of upper respiratory tract infections among these students during finals week. It is hypothesized that the stress of studying for examinations adversely affects the immune system, making the students more susceptible to infection. Which of the following laboratory findings in these students during examination week is most likely to support this hypothesis?

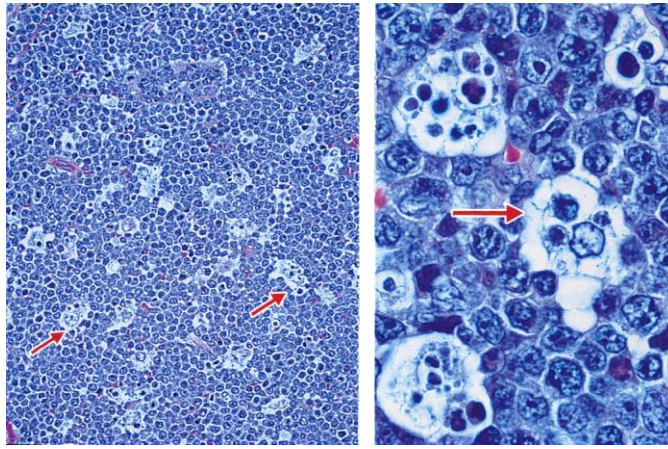
- (A) Decreased AM serum cortisol concentration
- (B) Decreased macrophage activity
- (C) Increased basophil count
- (D) Increased lymphocyte count
- (E) Increased natural killer cell activity

21. A 63-year-old man is brought to the emergency department because of a 4-day history of increasingly severe left leg pain and swelling of his left calf. He also has a 1-month history of increasingly severe upper midthoracic back pain. During this time, he has had a 9-kg (20-lb) weight loss despite no change in appetite. He has no history of major medical illness. His only medication is ibuprofen. He is 180 cm (5 ft 11 in) tall and weighs 82 kg (180 lb); BMI is 25 kg/m². His vital signs are within normal limits. On examination, lower extremity pulses are palpable bilaterally. The remainder of the physical examination shows no abnormalities. An x-ray of the thoracic spine shows no abnormalities. A CT scan of the abdomen shows a 3-cm mass in the body of the pancreas; there are liver metastases and encasement of the superior mesenteric artery. Ultrasonography of the left lower extremity shows a femoropopliteal venous clot. Which of the following is the most likely cause of this patient's symptoms?

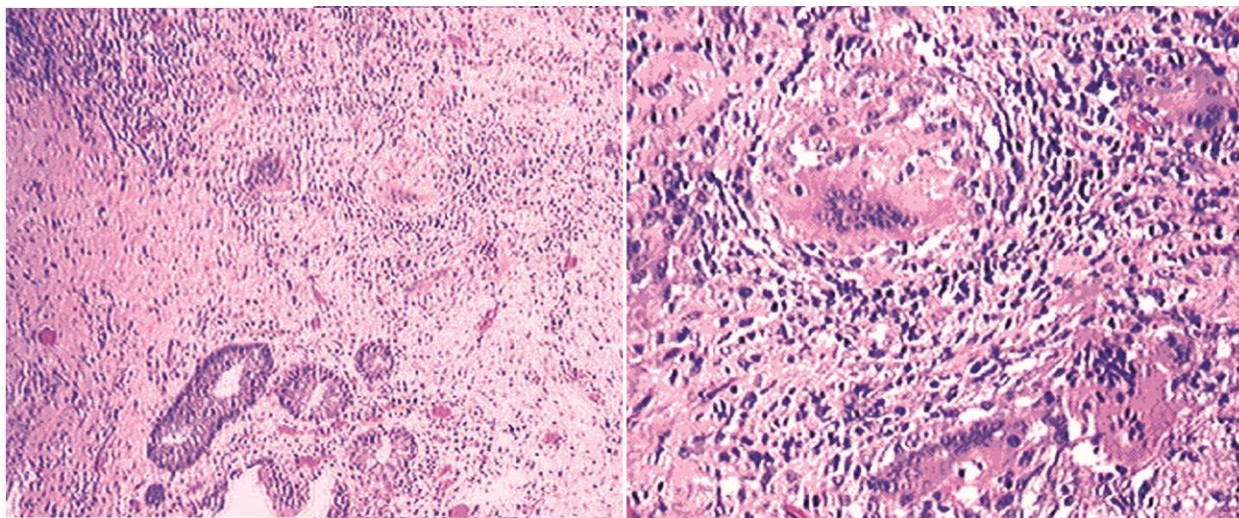
- (A) Carcinoid syndrome
- (B) Hypercoagulability from advanced malignancy
- (C) Multiple endocrine neoplasia
- (D) Splenic artery aneurysm and embolic disease of the left lower extremity
- (E) Superior mesenteric artery syndrome

22. A 35-year-old man comes to the physician because of pain and swelling of his right arm where he scraped it on a tree branch 2 days ago. His temperature is 38.3°C (101°F). Examination of the right forearm shows edema around a fluctuant erythematous lesion at the site of trauma. The area is extremely tender to palpation. Which of the following is most likely the primary mechanism of the development of edema in this patient?

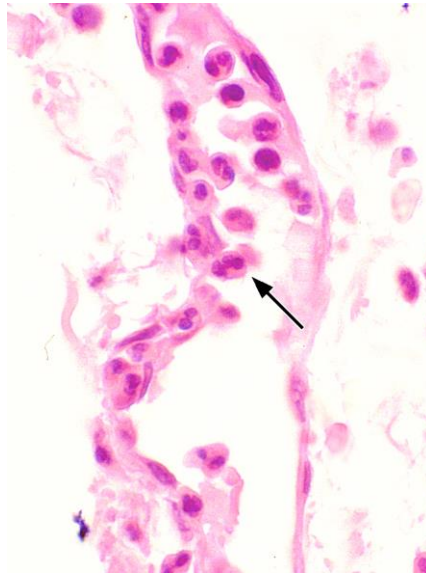
- (A) Degranulation of eosinophils
- (B) Disruption of vascular basement membranes
- (C) Increased hydrostatic pressure
- (D) Release of thromboxane
- (E) Separation of endothelial junctions



23. A 4-year-old boy from Brazil is brought to the physician because of a 1-week history of painless swelling of his jaw and pressure around his eyes. He is at the 80th percentile for height and weight. Physical examination shows a single 12 × 10-cm lesion in the right side of the jaw with diffuse limits and irregular edges. Photomicrographs of an incisional biopsy specimen of the lesion are shown. Based on these findings, which of the following processes is most likely occurring in the region indicated by the arrows?
- (A) Apoptosis
 - (B) Necrosis
 - (C) Oncosis
 - (D) Ostosis
 - (E) Symptosis
-
24. A 33-year-old woman comes to the physician because of a 2-day history of mild nausea, increased urinary urgency and frequency, and constipation. She also has had a 4.5-kg (10-lb) weight loss during the past 2 weeks and a 3-week history of vaginal bleeding. Pelvic examination shows a nodular cervix with an irregular, friable posterior lip, and a rock-hard, irregular, immobile pelvic mass that extends across the pelvis. Examination of biopsy specimens from the cervix and anterior wall of the vagina show well-differentiated keratinizing squamous cell carcinoma. Which of the following best describes the pathogenesis of this patient's disease?
- (A) Inactivation of cellular p53
 - (B) Insertion of viral promoters adjacent to cellular growth factor genes
 - (C) Specialized transduction
 - (D) Transactivation of cellular growth factor genes by *TAX*
 - (E) Translocation of *CMYC* to an Ig gene promoter
25. A 27-year-old man is admitted to the hospital 45 minutes after being involved in a motor vehicle collision. Physical examination shows a sluggish response to stimuli. Neurologic examination shows no other abnormalities. A skull x-ray shows a linear, nondepressed basal skull fracture. Two weeks later, the patient develops polyuria and polydipsia. Laboratory studies show a serum glucose concentration within the reference range, increased serum osmolality, and decreased urine osmolality. Following the administration of desmopressin, urine osmolality increases. The beneficial effect of this drug is most likely due to activation of which of the following?
- (A) Adenylyl cyclase
 - (B) Ca^{2+} channels
 - (C) Janus kinase
 - (D) Serine kinase
 - (E) Tyrosine kinase



26. A 30-year-old man is admitted to the hospital for evaluation. He has a 6-week history of colicky abdominal pain and diarrhea with occasional blood. Three days after admission, he suddenly develops peritonitis and sepsis. Despite appropriate care, he dies. At autopsy, examination shows a fibrinous exudate over the peritoneal and serosal surfaces, and a punctate opening is seen in the wall of a thickened loop of small intestine. Several lengths of the small and large intestines are also thickened and adherent to one another, with marked areas of narrowing. Photomicrographs of a section of the colon are shown. Which of the following is the most likely diagnosis?
- (A) Colon cancer
 - (B) Crohn disease
 - (C) Diverticulitis
 - (D) Ischemic necrosis
 - (E) Ulcerative colitis
-
27. A couple comes for preconceptional genetic counseling because they both have a family history of α -thalassemia. The woman has a minimally decreased hemoglobin concentration. Genetic studies show a single gene deletion. The man has microcytic anemia and a two-gene deletion. If the two-gene deletion is in *trans* (one deletion on the maternal gene and one deletion on the paternal gene), which of the following percentages of their offspring will have a two-gene deletion?
- (A) 0%
 - (B) 25%
 - (C) 50%
 - (D) 75%
 - (E) 100%
28. A healthy 22-year-old man participates in a study of glucose metabolism. At the beginning of the study, his serum glucose concentration is within the reference range. He consumes an 800-calorie meal consisting of protein, fat, and carbohydrates. He then sleeps through the night without additional food or drink. Twelve hours later, his serum glucose concentration remains within the reference range. Which of the following mechanisms is most likely involved in maintaining this man's serum glucose concentration?
- (A) Continued gut absorption of calories from the ingested meal
 - (B) Glucose release from skeletal muscle
 - (C) Glycogenolysis in the liver
 - (D) Increased leptin release from adipose tissues
 - (E) Inhibition of glucagon release by the pancreas



29. A 63-year-old homeless man is brought to the emergency department 1 hour after police found him unresponsive. His respirations are 30/min. Crackles are heard over the left upper and the entire right lung fields. Despite appropriate lifesaving measures, he dies. A photomicrograph of a section of the right lung obtained at autopsy is shown. Which of the following mediators is the most likely cause of the position of the cell indicated by the arrow?
- (A) Bradykinin
 - (B) C5a
 - (C) Histamine
 - (D) Nitrous oxide
 - (E) Prostaglandins
-
30. A 16-year-old boy is brought to the physician because of a 3-day history of abdominal pain and vomiting; he also has had decreased appetite during this period. The pain was initially on the right but now has become generalized. His temperature is 38.8°C (101.8°F), pulse is 100/min, respirations are 20/min, and blood pressure is 143/83 mm Hg. Abdominal examination shows guarding with diffuse rebound tenderness. There are no palpable masses. A CT scan of the abdomen shows a perforated appendix. Examination of peritoneal fluid from this patient will most likely show which of the following organisms?
- (A) *Candida albicans*
 - (B) *Citrobacter freundii*
 - (C) *Escherichia coli*
 - (D) *Staphylococcus aureus*
 - (E) *Streptococcus pneumoniae*
31. A 16-year-old boy is admitted to the emergency department because of a knife wound to the left side of his chest. An x-ray of the chest shows an air-fluid level in the left side of the chest, partial collapse of the left lung, and elevation of the stomach bubble. The mediastinum is in the midline. Which of the following is the most likely diagnosis?
- (A) Hemopneumothorax, not under tension
 - (B) Hemothorax, not under tension
 - (C) Pneumothorax, not under tension
 - (D) Tension hemopneumothorax
 - (E) Tension hemothorax
 - (F) Tension pneumothorax

32. A 20-year-old woman comes to the physician because of a 5-year history of heavy bleeding with menses that often requires her to change her sanitary pads three times hourly. Menses occur at regular 28-day intervals. She recently sustained a minor cut to her finger, and the bleeding took longer to stop than usual. She has not had easy bruising or change in weight. She only takes an oral contraceptive, but she has not been sexually active for the past 6 months. Her temperature is 37.5°C (99.5°F), pulse is 72/min, respirations are 12/min, and blood pressure is 120/66 mm Hg. Physical examination shows mildly pale conjunctivae. Pelvic examination shows no abnormalities. Laboratory studies show:

| | |
|---|-------------------------|
| Hemoglobin | 10.5 g/dL |
| Hematocrit | 31.3% |
| Mean corpuscular hemoglobin concentration | 28% Hb/cell |
| Mean corpuscular volume | 70 μm^3 |
| Leukocyte count | 5500/mm ³ |
| Platelet count | 275,000/mm ³ |
| Platelet aggregation studies | normal |
| Prothrombin time | 10.5 sec (INR=1.0) |
| Partial thromboplastin time | 28 sec |

A Pap smear shows no abnormalities. Which of the following hematologic disorders is the most likely cause of this patient's menorrhagia?

- (A) Afibrinogenemia
- (B) Hemophilia A
- (C) Intravascular coagulation
- (D) Vitamin K deficiency
- (E) von Willebrand disease

-
33. A 2-year-old boy is brought to the physician for a well-child examination. He was delivered at term after an uncomplicated pregnancy. His birth weight was 3500 g (7 lb 11 oz), and Apgar scores were 8 and 10 at 1 and 5 minutes, respectively. At the age of 15 months, physical examination showed no abnormalities, but he was not yet talking. Both of his parents had learning difficulties in school, and his mother stopped attending after the 10th grade. He has a maternal uncle with cognitive disabilities. He is at the 25th percentile for height, 15th percentile for weight, and 90th percentile for head circumference. He appears irritable, he resists making eye contact, and he is flapping his hands. Which of the following is the most likely cause of this patient's condition?

- (A) Creation of an alternative splice site
- (B) Frameshift mutation
- (C) Missense mutation
- (D) Nonsense mutation
- (E) Trinucleotide repeat expansion

34. A 31-year-old woman with type 2 diabetes mellitus comes to the physician because of an oozing, foul-smelling wound on her foot for 2 days. Physical examination shows a 4-cm, necrotizing wound with a purplish black discoloration over the heel. Crepitant bullae producing profuse amounts of serous drainage are seen. A Gram stain of a tissue biopsy specimen shows gram-positive rods. The causal organism most likely produces which of the following virulence factors?

- (A) Endotoxin
- (B) Fimbriae
- (C) Pneumolysin
- (D) Polysaccharide capsule
- (E) α -Toxin

35. A 10-month-old boy is brought to the physician because of a 4-day history of fever and cough. His illness began with low-grade fever and copious, clear nasal discharge. Two days ago he developed a moist, nonproductive cough and rapid breathing. He has received all scheduled childhood immunizations. He attends a large day-care center and has three school-aged siblings. His temperature is 38°C (100.4°F), pulse is 101/min, respirations are 38/min, and blood pressure is 85/60 mm Hg. Physical examination shows nasal flaring and rhinorrhea. Chest examination shows intercostal retractions along with bilateral, diffuse wheezes and expiratory rhonchi. The infectious agent of this patient's condition most likely has which of the following properties?
- (A) DNA genome
 - (B) Double-stranded nucleic acid genome
 - (C) Mature virion lacking viral polymerase
 - (D) Mediation of cell entry via a fusion protein
 - (E) Viability on surfaces for several weeks
36. A 17-year-old girl is brought to the emergency department 15 minutes after being stung by a bee. She has mild light-headedness but no difficulty swallowing. Her temperature is 37.1°C (98.8°F), pulse is 100/min, respirations are 30/min, and blood pressure is 115/70 mm Hg. Physical examination shows no urticaria. Bilateral wheezing is heard on auscultation of the chest. Which of the following types of drugs is the most appropriate pharmacotherapy for this patient?
- (A) α_1 -Adrenergic agonist
 - (B) α_2 -Adrenergic agonist
 - (C) α_1 -Adrenergic antagonist
 - (D) β_2 -Adrenergic agonist
 - (E) β_2 -Adrenergic antagonist
37. A 30-year-old woman, gravida 2, para 0, aborta 1, at 28 weeks' gestation comes to the office for a prenatal visit. She has had one previous pregnancy resulting in a spontaneous abortion at 12 weeks' gestation. Today, her vital signs are within normal limits. Physical examination shows a uterus consistent in size with a 28-week gestation. Fetal ultrasonography shows a male fetus with no abnormalities. Her blood group is O, Rh-negative. The father's blood group is B, Rh-positive. The physician recommends administration of Rh₀(D) immune globulin to the patient. This treatment is most likely to prevent which of the following in this mother?
- (A) Development of natural killer cells
 - (B) Development of polycythemia
 - (C) Formation of antibodies to RhD
 - (D) Generation of IgM antibodies from fixing complement in the fetus
 - (E) Immunosuppression caused by RhD on erythrocytes from the fetus
38. A 52-year-old woman begins pharmacotherapy after being diagnosed with type 2 diabetes mellitus. Four weeks later, her hepatic glucose output is decreased, and target tissue glucose uptake and utilization are increased. Which of the following drugs was most likely prescribed for this patient?
- (A) Acarbose
 - (B) Glyburide
 - (C) Metformin
 - (D) Nateglinide
 - (E) Repaglinide

39. A sexually active 23-year-old man with multiple sex partners has dysuria and a yellow urethral exudate. Gram stain of the exudate shows numerous neutrophils, many that contain intracellular gram-negative diplococci. He has had three similar episodes of urethritis over the past 2 years. Which of the following properties of the infecting organism best explains the reinfection?
- (A) Antigenic variation
 - (B) Catalase
 - (C) Inhibition of B-lymphocyte function
 - (D) Inhibition of T-lymphocyte function
 - (E) Polysaccharide capsule
40. A 17-year-old girl is brought to the physician by her mother because she has not had a menstrual period for 6 months. The patient is unconcerned about the lack of menses. Menarche occurred at the age of 12 years, and menses had occurred at regular 28-day intervals until they became irregular 1 year ago. She is a member of her high school gymnastics team. She appears emaciated. She is 163 cm (5 ft 4 in) tall and weighs 40 kg (88 lb); BMI is 15 kg/m². Her pulse is 54/min, and blood pressure is 80/50 mm Hg. Which of the following is the most likely cause of this patient's amenorrhea?
- (A) Hyperthyroidism
 - (B) Hypogonadotropic hypogonadism
 - (C) Hypothyroidism
 - (D) Polycystic ovarian syndrome
 - (E) Prolactinoma

USMLE STEP 1 SAMPLE TEST QUESTIONS

BLOCK 2, ITEMS 41-80

41. A 49-year-old woman comes to the physician for a follow-up examination. She has a strong family history of coronary artery disease. Her blood pressure has ranged from 150/95 mm Hg to 130/85 mm Hg during the previous three visits within the past 2 months. Her blood pressure today is 140/90 mm Hg. Physical examination shows no other abnormalities. Laboratory studies show:

| | |
|--------------------|-----------|
| Cholesterol, total | 290 mg/dL |
| HDL-cholesterol | 40 mg/dL |
| LDL-cholesterol | 190 mg/dL |
| Triglycerides | 350 mg/dL |

Treatment with atorvastatin and losartan is initiated. Which of the following serum findings is most likely to occur in this patient?

| | HDL-cholesterol | Triglycerides |
|-----|------------------------|----------------------|
| (A) | Decreased | decreased |
| (B) | Decreased | increased |
| (C) | Increased | decreased |
| (D) | Increased | increased |
| (E) | No change | no change |

42. A 15-year-old girl comes to the physician because of a 3-month history of acne. Breast and pubic hair development began at the age of 12 years. Menarche occurred at the age of 14 years. Physical examination shows scattered open and closed comedones over the cheeks and forehead. Breast and pubic hair development are Tanner stage 5. Which of the following is the most likely underlying cause of this patient's acne?

- (A) Decreased parasympathetic stimulation to the sebaceous glands
- (B) Increased estrogen stimulation of the sebaceous glands
- (C) Increased responsiveness of the sebaceous glands to follicle-stimulating hormone
- (D) Increased sympathetic stimulation to the sebaceous glands
- (E) Stimulation of the sebaceous glands by androgens

43. A previously healthy 40-year-old man is brought to the emergency department because of constant substernal chest pain for 12 hours that is exacerbated by coughing and inspiration. The pain is relieved with sitting up and leaning forward. There is no family history of heart disease. His temperature is 38°C (100.4°F), pulse is 120/min, and blood pressure is 110/60 mm Hg. The lungs are clear to auscultation. Cardiac examination shows distant heart sounds. An ECG shows diffuse ST-segment elevation in all leads. An x-ray of the chest shows normal findings. The most likely cause of his condition is injury to which of the following tissues?

- (A) Aortic intima
- (B) Esophageal sphincter
- (C) Myocardium
- (D) Pericardium
- (E) Pleura

44. A 55-year-old man is brought to the emergency department because of shortness of breath and confusion for 4 hours. He has hypertension and chronic kidney disease requiring hemodialysis. An ECG shows low voltage with electrical alternans. Physical examination is most likely to show which of the following findings?

| | Blood Pressure (mm Hg) | Pulse (/min) | Jugular Venous Pressure | Pulsus Paradoxus |
|-----|-----------------------------------|---------------------|------------------------------------|-----------------------------|
| (A) | 85/60 | 120 | increased | increased |
| (B) | 85/60 | 120 | increased | normal |
| (C) | 85/60 | 120 | normal | normal |
| (D) | 120/80 | 80 | increased | increased |
| (E) | 120/80 | 80 | normal | increased |
| (F) | 120/80 | 80 | normal | normal |

45. A 54-year-old woman comes to the emergency department because of severe jaw pain since undergoing a painful dental procedure 1 day ago. The patient was prescribed codeine after the procedure and instructed to take the medication every 4 hours, but she has continued pain despite adherence to this analgesic regimen. Other members of her family also have experienced poor pain control with codeine. Which of the following is the most likely explanation for this therapeutic failure?

- (A) Decreased absorption of codeine
- (B) Decreased metabolism of codeine to morphine
- (C) Deficiency of κ receptors
- (D) Increased plasma protein-binding of codeine
- (E) Increased renal clearance of codeine

46. A 14-year-old girl with a 9-year history of type 1 diabetes mellitus is brought to the physician by her mother for a follow-up examination. She has been admitted to the hospital twice in the past 3 months because of diabetic ketoacidosis. She previously had been compliant with monitoring her blood glucose concentration and with her diet and insulin regimen. She acknowledges that, when she is with her peers, she eats whatever she wants and does not check her blood glucose concentration. She adds, "I'm embarrassed to inject myself in front of them." The physician is having a great deal of difficulty with her 15-year-old son who has been truant from school and sneaking out of the house. She says to the patient, "You should be ashamed for not taking care of yourself. We've all worked so hard to keep you healthy." Which of the following terms best describes the physician's reaction to the patient?

- (A) Countertransference
- (B) Identification with the aggressor
- (C) Projection
- (D) Splitting
- (E) Sublimation

47. A 23-year-old woman with bone marrow failure is treated with a large dose of rabbit antithymocyte globulin. Ten days later, she develops fever, lymphadenopathy, arthralgias, and erythema on her hands and feet. Which of the following is the most likely cause of these symptoms?

- (A) Cytokine secretion by natural killer cells
- (B) Eosinophil degranulation
- (C) Immune complex deposition in tissues
- (D) Polyclonal T-lymphocyte activation
- (E) Widespread apoptosis of B lymphocytes

48. A 25-year-old man is brought to the emergency department because of a 6-day history of fever, severe muscle pain, and diffuse, painful swelling of his neck, underarms, and groin area. The symptoms began after returning from a camping trip in New Mexico. He appears ill and lethargic and can barely answer questions. His temperature is 39.2°C (102.5°F), pulse is 120/min, respirations are 22/min, and blood pressure is 110/70 mm Hg. Physical examination shows generalized scattered black maculae. Examination of the right upper extremity shows an erythematous, solid, tender mass on the underside of the upper extremity just above the elbow; the mass is draining blood and necrotic material. The most effective antibiotic for this patient's disorder will interfere with which of the following cellular processes or enzymes?

- (A) Cell wall synthesis
- (B) DNA helicase
- (C) Glucuronosyltransferase
- (D) Proteasomal degradation
- (E) Ribosomal assembly
- (F) Tetrahydrofolate reductase

49. A 42-year-old woman comes to the physician because of anxiety, tremor, and a 5-kg (11-lb) weight loss over the past 4 months despite good appetite. Physical examination shows fine thin hair, exophthalmos, goiter, and warm moist skin. Cardiac examination shows tachycardia and a widened pulse pressure. Which of the following sets of laboratory values is most likely in this patient's serum?

| | Thyroid-stimulating Hormone | Total Thyroxine (T ₄) | Free Thyroxine | Thyroid-binding Globulin |
|-----|--------------------------------|--------------------------------------|-------------------|-----------------------------|
| (A) | ↑ | ↑ | ↑ | ↑ |
| (B) | ↑ | ↑ | normal | ↓ |
| (C) | ↑ | normal | ↑ | ↓ |
| (D) | ↓ | ↑ | ↑ | normal |
| (E) | ↓ | normal | normal | ↑ |
| (F) | ↓ | normal | normal | normal |

50. A 29-year-old woman is prescribed carbamazepine for trigeminal neuralgia. She has a strong family history of osteoporosis. As a result, the physician also advises her to increase her intake of vitamin D. The most likely reason for this recommendation is that carbamazepine may affect which of the following pharmacokinetic processes?

- (A) Absorption
- (B) Distribution
- (C) Excretion
- (D) Metabolism
- (E) Protein binding

51. Over 1 year, a study is conducted to assess the antileukemic activity of a new tyrosine kinase inhibitor in patients with chronic myeloid leukemia in blast crisis. All patients enrolled in the study are informed that they would be treated with the tyrosine kinase inhibitor. They are assigned to successive dose cohorts of 300 to 1000 mg/day of the drug. Six to eight patients are assigned to each dose. Treatment efficacy is determined based on the results of complete blood counts and bone marrow assessments conducted regularly throughout the study. This study is best described as which of the following?

- (A) Case-control study
- (B) Crossover study
- (C) Open-labeled clinical trial
- (D) Randomized clinical trial
- (E) Single-blind, randomized, controlled trial

52. A 64-year-old man with non-Hodgkin lymphoma comes to the physician because of a 3-week history of progressive numbness in his hands and feet and weakness in his legs when he stands. He received his third course of chemotherapy 4 weeks ago. Physical examination shows areflexia. Which of the following drugs is the most likely cause of these adverse effects?
- (A) Bleomycin
 - (B) Cyclophosphamide
 - (C) Cytarabine
 - (D) Doxorubicin
 - (E) Fluorouracil
 - (F) Methotrexate
 - (G) Vincristine

53. During an experiment, drug X is added to a muscle bath containing a strip of guinea pig intestinal smooth muscle. Agonists are added to the bath, and the resultant effects on muscle tension are shown in the table.

| Agonist | Muscle Tension Before Drug X (g) | Muscle Tension After Drug X (g) |
|----------------|----------------------------------|---------------------------------|
| Vehicle | 6.0 | 6.1 |
| Acetylcholine | 11.3 | 18.5 |
| Norepinephrine | 4.1 | 4.2 |

Which of the following types of drugs is most likely to produce effects most similar to those of drug X?

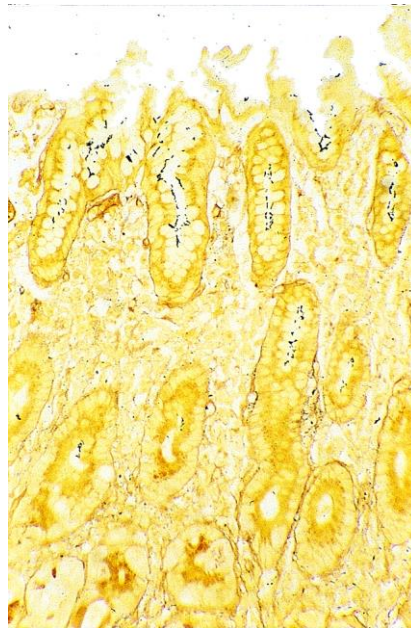
- (A) α_1 -Adrenergic antagonist
 - (B) β -Adrenergic antagonist
 - (C) Cholinesterase inhibitor
 - (D) Monoamine oxidase inhibitor
 - (E) Muscarinic antagonist
-
54. A 42-year-old man comes to the physician for a follow-up examination. Four months ago, he underwent repair of a Dupuytren contracture. Physical examination shows decreased range of motion in the affected hand. The patient is upset that his hand has not fully healed, and he files a malpractice suit against the physician. Which of the following is the most likely precipitating factor in this patient's decision to file a malpractice suit?
- (A) The patient's perception that the physician is incompetent
 - (B) The patient's perception that the physician is uncaring
 - (C) The patient's socioeconomic status
 - (D) The physician's amount of experience in the medical field
 - (E) The physician's inability to screen out problem patients
55. A 72-year-old woman comes to the physician because of a 2-month history of painless swelling of both ankles. She also reports shortness of breath with exertion and when lying down. She has awakened from sleep by shortness of breath. She has not had chest pain. Her pulse is 96/min and regular, respirations are 24/min, and blood pressure is 128/76 mm Hg. Jugular venous pressure is 15 cm H₂O. Pulmonary examination shows crackles at both lung bases. Cardiac examination shows a regular rhythm and a soft S₃. A grade 3/6 holosystolic murmur is heard best at the apex, radiating to the axilla. There is 2+ pitting edema of the lower legs and ankles. Which of the following is most likely to confirm the diagnosis?
- (A) Measurement of serum troponin I concentration
 - (B) ECG
 - (C) Exercise stress test
 - (D) Echocardiography
 - (E) Pulmonary artery catheterization

56. A 14-year-old boy is brought to the physician for a physical examination prior to participating in sports. He appears reluctant to remove his shirt for the examination, and says that he is embarrassed because he has grown breasts during the past year. He is at the 50th percentile for height and weight. Physical examination shows bilateral 1.5-cm fibroglandular masses located beneath the nipple-areolar complex and normal penis and testes. Pubic hair development is Tanner stage 3. Serum concentrations of gonadotropic hormones, estrogens, and testosterone are within the reference ranges. Which of the following is the most likely cause of this patient's breast enlargement?
- (A) Breast adenocarcinoma
 - (B) Estradiol-secreting Leydig cell tumor
 - (C) Peutz-Jeghers syndrome
 - (D) Seminiferous tubule dysgenesis (Klinefelter syndrome)
 - (E) Normal development
57. A 5-year-old boy is admitted to the hospital because of a 1-week history of fever and increasingly severe abdominal discomfort. At the age of 7 months, he was treated for osteomyelitis caused by *Aspergillus fumigatus*. He has been admitted to the hospital three times during the past 4 years for severe pneumonia. He appears moderately ill. His temperature is 39°C (102.2°F). Abdominal examination shows an enlarged, tender liver. Ultrasonography of the abdomen shows an intrahepatic abscess. Culture of the abscess fluid grows *Staphylococcus aureus*. Further analysis shows failure of the neutrophils to undergo an oxidative burst when exposed to *S. aureus*. This patient has an increased susceptibility to infection as a result of which of the following abnormalities?
- (A) Deficient leukocyte production
 - (B) Failure of leukocytes to migrate between endothelial cells
 - (C) Failure of leukocytes to roll along the endothelial surface
 - (D) Inability of leukocytes to ingest microorganisms
 - (E) Inability of leukocytes to kill intracellular microorganisms
58. A 22-year-old woman contacts a medical student and asks if he would like to join her for dinner. The student met the woman when he was assigned to her care during her 2-week hospitalization for treatment of major depressive disorder. He has not treated or seen the patient since she was discharged from the hospital. He is attracted to this former patient and would be interested in dating her. Which of the following is the most appropriate action by the medical student regarding this patient's invitation?
- (A) He can date her because he was a medical student, not a physician, when he contributed to her care
 - (B) He can date her because she is no longer his patient
 - (C) He can date her, but only after at least 1 year has passed since he treated her
 - (D) He cannot date her because she was once his psychiatric patient
 - (E) He cannot date her unless she agrees never to seek care at his hospital in the future
59. A 73-year-old woman comes to the physician because of a 2-month history of diffuse weakness and tingling of her arms and legs. Neurologic examination shows weakness of the extensor and flexor muscles of the lower extremities. Knee and ankle deep tendon reflexes are exaggerated. Sensation to vibration and position is decreased in all extremities, but the decrease is more prominent in the lower extremities than in the upper extremities. This patient most likely has a deficiency of which of the following vitamins?
- (A) Niacin
 - (B) Vitamin B₁ (thiamine)
 - (C) Vitamin B₂ (riboflavin)
 - (D) Vitamin B₆ (pyridoxine)
 - (E) Vitamin B₁₂ (cyanocobalamin)

60. A 45-year-old man comes to the physician because of right shoulder pain that began after he chopped wood 2 days ago. Examination of the right upper extremity shows no obvious bone deformities or point tenderness. The pain is reproduced when the patient is asked to externally rotate the shoulder against resistance; there is no weakness. In addition to the teres minor, inflammation of which of the following tendons is most likely in this patient?
- (A) Infraspinatus
 - (B) Pectoralis
 - (C) Subscapularis
 - (D) Supraspinatus
 - (E) Trapezius
61. A 54-year-old man comes to the physician for a follow-up examination 10 days after undergoing a stereotactic brain operation to remove a small tumor. The operation was successful. During the procedure, he was under conscious sedation. The patient recalls that at one point during the operation he experienced a sudden, intense feeling of overwhelming fear. Which of the following areas of the brain was most likely stimulated at that time?
- (A) Amygdala
 - (B) Hippocampus
 - (C) Mammillary body
 - (D) Prefrontal cortex
 - (E) Thalamus
62. A placebo-controlled clinical trial is conducted to assess whether a new antihypertensive drug is more effective than standard therapy. A total of 5000 patients with essential hypertension are enrolled and randomly assigned to one of two groups: 2500 patients receive the new drug and 2500 patients receive placebo. If the alpha is set at 0.01 instead of 0.05, which of the following is the most likely result?
- (A) Significant findings can be reported with greater confidence
 - (B) The study will have more power
 - (C) There is a decreased likelihood of a Type II error
 - (D) There is an increased likelihood of statistically significant findings
 - (E) There is an increased likelihood of a Type I error
63. A male stillborn is delivered at 32 weeks' gestation to a 30-year-old woman. The pregnancy was complicated by oligohydramnios. Examination of the stillborn shows the absence of a urethral opening. Which of the following additional findings is most likely in this stillborn?
- (A) Congenital diaphragmatic hernia
 - (B) Intralobar sequestration
 - (C) Pulmonary hypoplasia
 - (D) Situs inversus
 - (E) Tracheoesophageal fistula
64. A 33-year-old man undergoes a radical thyroidectomy for thyroid cancer. During the operation, moderate hemorrhaging requires ligation of several vessels in the left side of the neck. Postoperatively, serum studies show a calcium concentration of 7.5 mg/dL, albumin concentration of 4 g/dL, and parathyroid hormone concentration of 200 pg/mL. Damage to which of the following vessels caused the findings in this patient?
- (A) Branch of the costocervical trunk
 - (B) Branch of the external carotid artery
 - (C) Branch of the thyrocervical trunk
 - (D) Tributary of the internal jugular vein
 - (E) Tributary of the left brachiocephalic vein
 - (F) Tributary of the right brachiocephalic vein

65. A 42-year-old man comes to the physician for a follow-up examination 1 week after he passed a renal calculus. X-ray crystallographic analysis of the calculus showed calcium as the primary cation. Physical examination today shows no abnormalities. A 24-hour collection of urine shows increased calcium excretion. Which of the following is the most appropriate pharmacotherapy?
- (A) Carbonic anhydrase inhibitor
 - (B) $\text{Na}^+\text{-Cl}^-$ symport inhibitor
 - (C) $\text{Na}^+\text{-K}^+\text{-2Cl}^-$ symport inhibitor
 - (D) Osmotic diuretic
 - (E) Renal epithelial sodium channel inhibitor
66. A 55-year-old man comes to the physician because of a 2-week history of recurrent, widespread blister formation. Physical examination shows lesions that are most numerous in the flexural areas including the axillae and groin. The blisters do not break easily, and there are no oral lesions. These blisters are most likely the result of adhesion failure involving which of the following?
- (A) Basement membrane
 - (B) Dermal papillae
 - (C) Langerhans cells
 - (D) Melanocytes
 - (E) Merkel cells
67. A 24-year-old man is brought to the emergency department 40 minutes after he was involved in a motor vehicle collision. He was the unrestrained driver. He is conscious. Physical examination shows numerous lacerations and ecchymoses over the face. His vision is normal. Ocular, facial, and lingual movements are intact. The gag reflex is present. Sensation to pinprick is absent over the right side of the face anterior to the right ear, extending down along the full extent of the mandible to the chin. Sensation also is absent over the right side of the tongue. X-rays of the skull show fractures of the orbit, zygomatic arch, and infratemporal fossa. The most likely cause of these findings is a fracture affecting which of the following locations?
- (A) Foramen lacerum
 - (B) Foramen ovale
 - (C) Foramen rotundum
 - (D) Foramen spinosum
 - (E) Jugular foramen
68. A 55-year-old man who is a business executive is admitted to the hospital for evaluation of abdominal pain. He is polite to the physician but berates the nurses and other staff. The patient's wife and two of his three adult children arrive for a visit. The patient says with disgust that the missing child is and always has been worthless. Which of the following is the most likely explanation for this patient's behavior?
- (A) Countertransference
 - (B) Projection
 - (C) Projective identification
 - (D) Reaction formation
 - (E) Splitting

69. A 3-year-old boy with chronic granulomatous disease is brought to the physician because of a 3-week history of fever and warm, red lumps under both arms. His temperature is 38°C (100.4°F). Physical examination shows enlarged, 3-cm, erythematous axillary lymph nodes bilaterally. On palpation, the nodes are tender, fluctuant, and movable. Examination of a fine-needle aspirate from one of the nodes shows gram-positive cocci in clusters. Cultures of the aspirate grow yellow, β -hemolytic colonies that are catalase and coagulase positive. A polymerase chain reaction test shows *mecA*-positive organisms. Which of the following is the most appropriate pharmacotherapy for this patient?
- (A) Cefazolin
 - (B) Ciprofloxacin
 - (C) Penicillin G
 - (D) Rifampin
 - (E) Vancomycin
-



70. An otherwise healthy 45-year-old man comes to the physician because of a 3-week history of progressive epigastric heartburn and a 4.5-kg (10-lb) weight loss. The pain tends to be more severe at night and occurs 1 to 3 hours after meals during the day. He has had similar episodes with lesser intensity during the past year. Abdominal examination shows tenderness to deep palpation. Test of the stool for occult blood is positive. Endoscopy shows a bleeding 3-cm ulcer in the antrum of the stomach. A photomicrograph of Steiner silver-stained tissue (400x) from a biopsy of the gastric mucosa adjacent to the ulcer is shown. Which of the following processes is most likely to be involved?
- (A) Elaboration of proteases and urease with local tissue destruction
 - (B) Hyperacidity and gastric ulcer development
 - (C) Ingestion of preformed toxins in contaminated well water
 - (D) Spirochete invasion of gastric cells

71. A 10-year-old girl is brought to the office by her mother because her school nurse thinks that she may have Marfan syndrome. She is at the 95th percentile for height and 25th percentile for weight. Physical examination shows a narrow palate with dental crowding, long slender extremities, and joint laxity. Molecular testing for *FBN1* shows a single nucleotide difference that does not change the amino acid at that locus. Her mother is 163 cm (5 ft 4 in) tall. There is no clinical evidence of Marfan syndrome in the mother, but she has the same single nucleotide change as the patient. The same nucleotide change is found in 15 of 200 individuals without Marfan syndrome. Which of the following best describes the single nucleotide change in the patient and her mother?

- (A) It is a disease-causing mutation in the patient and her mother
- (B) It is a polymorphism
- (C) It is a sequence variant of unknown significance
- (D) It will change the folding of the protein
- (E) It will result in a truncated protein

72. A previously healthy 40-year-old woman is brought to the emergency department by her husband because of a 2-day history of fever, lethargy, and confusion. Her temperature is 38°C (100.4°F), pulse is 80/min, respirations are 18/min, and blood pressure is 140/90 mm Hg. Physical examination shows scattered petechiae and ecchymoses over the lower extremities. Neurologic examination shows moderate generalized motor weakness. She is oriented to person but not to place or time. Laboratory studies show:

| | |
|-----------------------------|---|
| Hemoglobin | 9 g/dL |
| Hematocrit | 27% |
| Leukocyte count | 8000/mm ³ with a normal differential |
| Platelet count | 15,000/mm ³ |
| Prothrombin time | 12 sec (INR=1.1) |
| Partial thromboplastin time | 30 sec |
| Serum | |
| Urea nitrogen | 25 mg/dL |
| Lactate dehydrogenase | 1000 U/L |

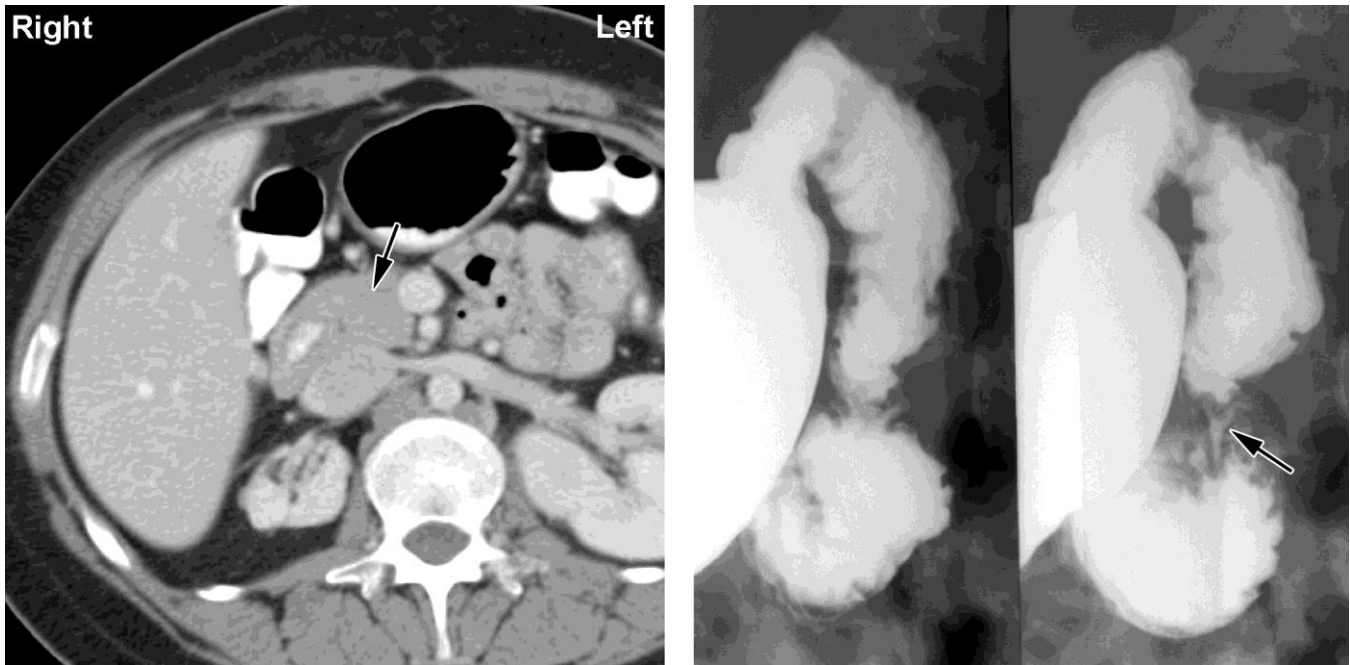
A peripheral blood smear shows 3+ polychromasia and 3+ schistocytes. Urine and blood cultures grow no organisms. A chest x-ray shows no abnormalities. Which of the following is the most likely diagnosis?

- (A) Acute myeloid leukemia
- (B) Autoimmune hemolytic anemia
- (C) Thrombotic thrombocytopenic purpura
- (D) Toxic shock syndrome
- (E) von Willebrand disease

73. A 17-year-old girl has never had a menstrual period. Physical examination shows a normal female body habitus, normal breast development, and normal appearing external genitalia. She has no axillary or pubic hair. The patient refuses to have a pelvic or rectal examination. Which of the following is the most likely explanation for the clinical presentation?

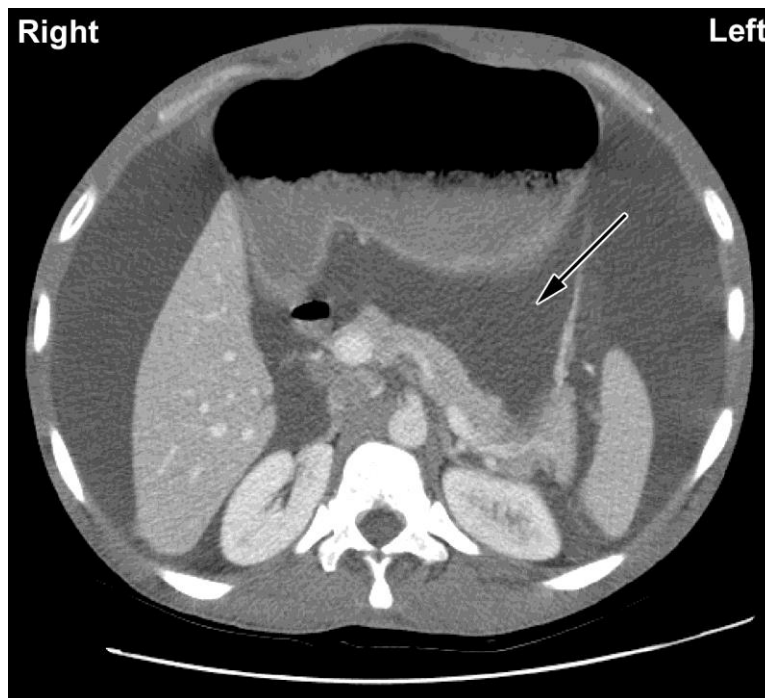
- (A) Androgen insensitivity
- (B) Congenital adrenal hyperplasia
- (C) Ectodermal dysplasia
- (D) A psychiatric disorder
- (E) A sex chromosome mosaicism

74. A 12-year-old girl is brought to the physician because of a 2-month history of intermittent yellowing of the eyes and skin. Physical examination shows no abnormalities except for jaundice. Her serum total bilirubin concentration is 3 mg/dL, with a direct component of 1 mg/dL. Serum studies show a haptoglobin concentration and AST and ALT activities that are within the reference ranges. There is no evidence of injury or exposure to toxins. Which of the following additional findings is most likely in this patient?
- (A) Decreased activity of UDP glucuronosyltransferase
 - (B) Gallstones
 - (C) Increased hemolysis
 - (D) Increased serum alkaline phosphatase activity
 - (E) Ineffective erythropoiesis
-



75. A 47-year-old woman comes to the emergency department because of a 2-week history of intermittent abdominal pain, nausea, and vomiting. She has had similar episodes sporadically during the past 4 years. Physical examination shows dehydration, jaundice, and upper abdominal distention. Laboratory studies show hyperbilirubinemia. A CT scan and upper gastrointestinal series of the abdomen with oral contrast are shown; the arrows indicate the abnormality. Which of the following is the most likely cause of these findings?
- (A) Annular pancreas
 - (B) Cirrhosis of the liver
 - (C) Duodenal constriction by the portal vein
 - (D) Duodenal constriction by the superior mesenteric artery
 - (E) Pyloric stenosis

76. An 8-year-old boy is brought to the office by his mother because of a 3-day history of fever, sore throat, and itchy eyes. He just returned from a weeklong summer camp that included hiking trips and swimming lessons in the camp-owned swimming pool. He has no history of major medical illness and receives no medications. He appears tired. His temperature is 39.4°C (102.9°F); other vital signs are within normal limits. Physical examination shows conjunctival injection and discharge and oropharyngeal erythema. The public health department reports an outbreak of similar symptoms among the other campers and camp volunteers. Which of the following is the most likely cause of this patient's symptoms?
- (A) Adenovirus
 - (B) Cytomegalovirus
 - (C) Epstein-Barr virus
 - (D) Influenza virus
 - (E) West Nile virus
-



77. A 36-year-old man with profound intellectual disability is brought to the physician by staff at his facility because of increasing abdominal girth during the past 2 weeks. He is unable to speak, and no medical history is currently available. Physical examination shows a protuberant abdomen with a fluid wave and shifting dullness. There are no signs of trauma to the area. Laboratory studies show no abnormalities. A CT scan of the abdomen is shown. Fluid is present in which of the following areas as indicated by the arrow?
- (A) Epiploic foramen
 - (B) Gastrosplenic ligament
 - (C) Hepatorenal pouch (of Morison)
 - (D) Omental bursa (lesser sac)
 - (E) Sulcus pericolicus

78. A study is designed to evaluate the feasibility of acupuncture in children with chronic headaches. Sixty children with chronic headaches are recruited for the study. In addition to their usual therapy, all children are treated with acupuncture three times a week for 2 months. Which of the following best describes this study design?
- (A) Case-control
(B) Case series
(C) Crossover
(D) Cross-sectional
(E) Historical cohort
(F) Randomized clinical trial
79. A 56-year-old man comes to the emergency department because of a 4-day history of colicky right flank pain that radiates to the groin and hematuria. Ultrasound examination of the kidneys shows right-sided hydronephrosis and a dilated ureter. Which of the following is most likely to be found on urinalysis?
- (A) Erythrocyte casts
(B) Glucose
(C) Leukocyte casts
(D) Oval fat bodies
(E) Uric acid crystals
80. A 62-year-old man comes to the physician for a follow-up examination after he was diagnosed with chronic inflammatory interstitial pneumonitis. Following pulmonary function testing, a biopsy specimen of the affected area of the lungs is obtained. Compared with a healthy man, analysis of this patient's biopsy specimen is most likely to show which of the following patterns of changes in the cell populations of alveoli?

| | Type I Pneumocytes | Type II Pneumocytes | Fibroblasts |
|-----|---------------------------|----------------------------|--------------------|
| (A) | ↑ | ↑ | ↑ |
| (B) | ↑ | ↑ | ↓ |
| (C) | ↑ | ↓ | ↑ |
| (D) | ↑ | ↓ | ↓ |
| (E) | ↓ | ↑ | ↑ |
| (F) | ↓ | ↑ | ↓ |
| (G) | ↓ | ↓ | ↑ |
| (H) | ↓ | ↓ | ↓ |

USMLE STEP 1 SAMPLE TEST QUESTIONS

BLOCK 3, ITEMS 81-117

81. Six healthy subjects participate in a study of muscle metabolism during which hyperglycemia and hyperinsulinemia is induced. Muscle biopsy specimens obtained from the subjects during the resting state show significantly increased concentrations of malonyl-CoA. The increased malonyl-CoA concentration most likely directly inhibits which of the following processes in these subjects?
- (A) Fatty acid oxidation
 - (B) Fatty acid synthesis
 - (C) Gluconeogenesis
 - (D) Glycogenolysis
 - (E) Glycolysis
 - (F) Oxidative phosphorylation
82. A 72-year-old woman who has smoked 20 cigarettes daily for the past 38 years begins using eyedrops for glaucoma. Three days later, she has a marked increase in shortness of breath while walking up a flight of stairs. Which of the following drugs is the most likely cause of the development of shortness of breath in this patient?
- (A) Acetazolamide
 - (B) Apraclonidine
 - (C) Epinephrine
 - (D) Latanoprost
 - (E) Timolol
83. A 54-year-old man comes to the physician because of episodes of fainting for 3 months. He also has had difficulty performing daily tasks because he is easily fatigued. He had a myocardial infarction 12 years ago. His pulse is 40/min, respirations are 18/min, and blood pressure is 138/85 mm Hg. Physical examination shows evidence of cannon *a* waves. An ECG shows a P-wave rate of 90/min, and an R-wave rate of 40/min, with no apparent relation between the two. Which of the following is the most likely diagnosis?
- (A) First-degree atrioventricular block
 - (B) Right bundle branch block
 - (C) Second-degree atrioventricular block, type I
 - (D) Second-degree atrioventricular block, type II
 - (E) Third-degree atrioventricular block
84. A 15-year-old boy is brought to the emergency department by his parents because of a 2-hour history of confusion and agitation. He also has had fever, headache, stiff neck, and vomiting since he returned from summer camp 2 days ago. His parents say he does not use illicit drugs. On arrival, he is combative and there is evidence of hallucinations. His temperature is 40°C (104°F), pulse is 80/min, respirations are 17/min, and blood pressure is 100/70 mm Hg. A lumbar puncture is performed. Results of cerebrospinal fluid analysis show cysts and trophozoites. The most likely portal of pathogen entry into this patient's central nervous system is which of the following?
- (A) Cavernous sinus
 - (B) Facial nerve
 - (C) Frontal sinus
 - (D) Mastoid sinus
 - (E) Olfactory nerve
 - (F) Trigeminal nerve

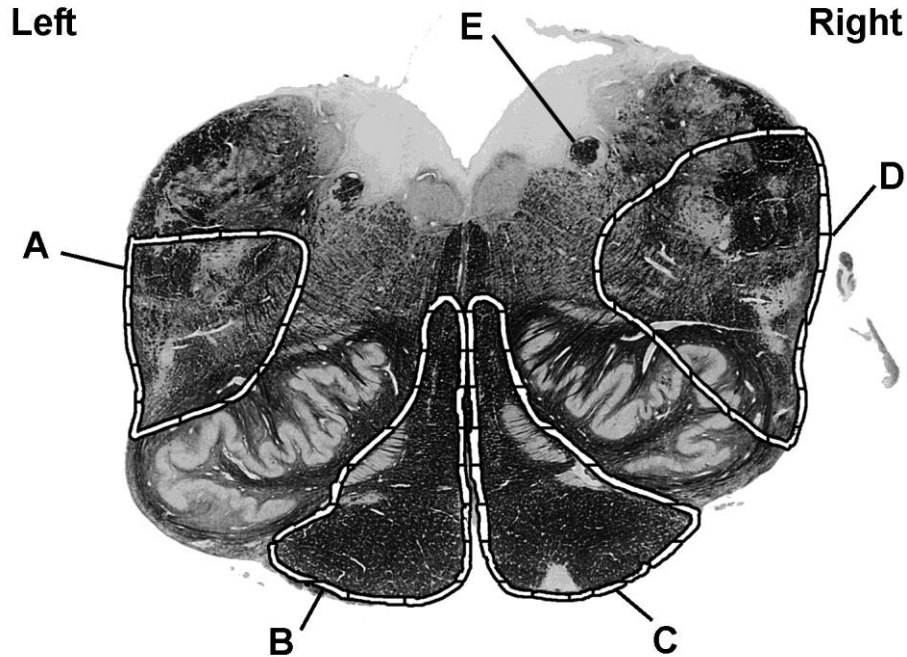
85. A 42-year-old woman comes to the physician for a routine examination. She says that she has felt well except for occasional episodes of constipation, abdominal discomfort, and mild fatigue. She was treated for a renal calculus 10 years ago and was told she had a "lazy gallbladder." Her pulse is 82/min, and blood pressure is 150/80 mm Hg. Physical examination shows no other abnormalities. Laboratory studies show:

| | |
|----------------------|---------------------------|
| Erythrocyte count | 3 million/mm ³ |
| Serum | |
| K ⁺ | 4.5 mEq/L |
| Cl ⁻ | 107 mEq/L |
| Ca ²⁺ | 12 mg/dL |
| Phosphorus | 2.2 mg/dL |
| Alkaline phosphatase | 95 U/L |

The most likely cause of this patient's condition is a small, well-defined nodule in which of the following locations?

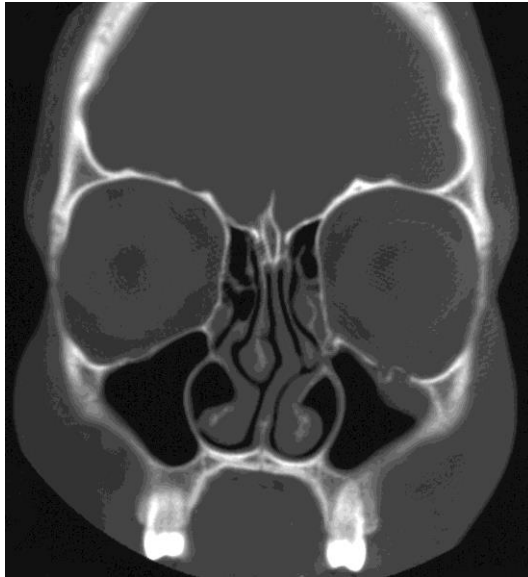
- (A) Adrenal gland
 - (B) Anterior pituitary gland
 - (C) Gallbladder
 - (D) Kidney
 - (E) Parathyroid gland
 - (F) Thymus
-
86. A new severe respiratory illness caused by a newly identified virus is discovered. Which of the following properties of a killed vaccine relative to a live vaccine is the most appropriate rationale for developing a killed vaccine for this illness?
- (A) Avoids the concern for reversion to virulence
 - (B) Develops more rapid protective immunity
 - (C) Is less likely to require subsequent boosters for lifelong immunity
 - (D) Is most likely to generate mucosal immunity
 - (E) Requires little safety monitoring to ensure inactivation
87. A 72-year-old woman comes to the physician because of a 3-day history of fever, shortness of breath, difficulty swallowing, chest pain, and cough. She is frail. Physical examination shows tachypnea and equal pulses bilaterally. Percussion of the chest shows dullness over the right lower lung field. Laboratory studies show arterial hypoxemia and decreased PCO₂. A chest x-ray shows an area of opacification in the lower region of the right lung. Which of the following is the most likely cause of this patient's condition?
- (A) Alveolar proteinosis
 - (B) Aspiration
 - (C) Cigarette smoking
 - (D) Emphysema
 - (E) Vasculitis
88. A 25-year-old woman comes to the office because of a 6-month history of increasingly severe low back pain and heavy menses. Her temperature is 37.1°C (98.8°F), pulse is 75/min, respirations are 13/min, and blood pressure is 115/79 mm Hg. Physical examination shows no abnormalities. An endometrial biopsy specimen shows regular tubular endometrial glands with abundant mitotic figures in the endometrial glands and stroma. Which of the following proteins or enzymes regulate the progression of cells into this phase of this patient's menstrual cycle?
- (A) AMP-dependent kinases
 - (B) Cyclin-dependent kinases
 - (C) Hexokinases
 - (D) Lipid kinases
 - (E) Urokinases

89. A 72-year-old woman is brought to the emergency department by her husband because of a 1-hour history of difficulty walking and speaking. The husband says that she was well last night but when she awoke this morning, she had difficulty getting out of bed and her speech was slurred. She has a 20-year history of type 2 diabetes mellitus well controlled with medication and diet. She is alert and oriented and is able to follow commands and respond verbally, but she has impaired speech. Her pulse is 80/min, respirations are 16/min, and blood pressure is 142/88 mm Hg. Physical examination shows left-sided hemiparesis. The tongue deviates to the right when protruded. Sensation to pinprick and temperature is normal, and proprioception and sensation to light touch are absent over the left upper and lower extremities. Which of the following labeled sites in the photograph of a cross section of a normal brain stem is most likely damaged in this patient?

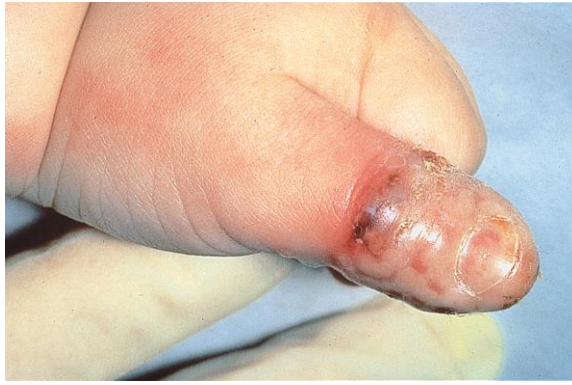

90. A 4-year-old boy is brought to the physician because of slow growth during the past year. He has had recurrent urinary tract infections since the age of 1 year. He is at the 10th percentile for height and 25th percentile for weight. Physical examination shows pallor. Laboratory studies show a normochromic, normocytic anemia and increased serum concentrations of urea nitrogen and creatinine. Urinalysis shows a low specific gravity. Which of the following sets of additional serum findings is most likely in this patient?

| | Calcium | Inorganic Phosphorus | 1,25-Dihydroxycholecalciferol | Erythropoietin |
|-----|---------|----------------------|-------------------------------|----------------|
| (A) | ↑ | ↑ | ↑ | ↓ |
| (B) | ↑ | ↑ | ↓ | ↓ |
| (C) | ↑ | ↓ | ↓ | ↑ |
| (D) | ↓ | ↑ | ↑ | ↓ |
| (E) | ↓ | ↑ | ↓ | ↓ |
| (F) | ↓ | ↓ | ↑ | ↑ |



91. A 42-year-old woman is brought to the emergency department because of double vision that began 20 minutes after she fell from her horse and landed on the left side of her face. Examination of the face shows ecchymoses over the left zygomatic arch. A CT scan of the head is shown. Which of the following arteries is at greatest risk for injury in this patient?
- (A) Facial
 - (B) Frontal
 - (C) Infraorbital
 - (D) Lacrimal
 - (E) Ophthalmic
-
92. A previously healthy 24-year-old woman who is a college student comes to the office because of a 6-month history of abdominal bloating, upper abdominal discomfort, and constipation. The symptoms are more severe when she is preparing for examinations but improve after bowel movements. She takes no medications. She does not smoke or use illicit drugs. She drinks alcoholic beverages occasionally. She is 160 cm (5 ft 3 in) tall and weighs 57 kg (125 lb); BMI is 22 kg/m². Her pulse is 72/min, and blood pressure is 100/72 mm Hg. Physical examination, including digital rectal examination, shows no other abnormalities. A complete blood count and serum electrolyte concentrations are within the reference ranges. A urease breath test result is negative. Upper and lower endoscopies show no abnormalities. Which of the following is the most appropriate pharmacotherapy for this patient?
- (A) Azathioprine
 - (B) Infliximab
 - (C) Lubiprostone
 - (D) Mesalamine
 - (E) Sulfasalazine
93. A 32-year-old man is brought to the emergency department 30 minutes after being struck by a car while driving his motorcycle. He reports severe pelvic pain. On examination, there is bruising of the perineum and pain is elicited with motion of his pelvis. Blood is noted at the urethral meatus. There is no other penile trauma. A plain x-ray shows a fracture of the superior pubic ramus and retrograde urethrography is done to evaluate for a urethral disruption. Which of the following portions of the urethra would be at greatest risk for injury in this patient?
- (A) Intramural (pre-prostatic)
 - (B) Membranous
 - (C) Prostatic
 - (D) Spongy



94. A 2-year-old boy is brought to the office by his mother because of a 1-day history of severe pain, swelling, and redness of his left thumb. The mother does not recall any trauma to the area. She says he has been eating poorly during this period, but otherwise he has been behaving normally. He has no history of major medical illness and receives no medications. He appears tearful. He is at the 90th percentile for length and 80th percentile for weight. His temperature is 37.7°C (99.8°F), pulse is 100/min, respirations are 20/min, and blood pressure is 100/50 mm Hg. Physical examination shows an oral vesicle, cervical lymphadenopathy, and the findings in the photograph. Which of the following types of infectious agents is the most likely cause of the findings in this patient's finger?
- (A) DNA virus
 - (B) Gram-negative bacterium
 - (C) Gram-positive bacterium
 - (D) RNA virus
 - (E) Yeast
-
95. A 46-year-old woman with active ankylosing spondylitis comes to the office for a follow-up examination. The use of various conventional nonsteroidal anti-inflammatory drugs has been ineffective. Sulfasalazine treatment also has not resulted in improvement. The most appropriate next step in treatment is administration of a drug that inhibits which of the following?
- (A) CD20
 - (B) Cyclooxygenase-2
 - (C) Cytotoxic T-lymphocyte antigen 4
 - (D) Epidermal growth factor
 - (E) Interleukin-1 (IL-1)
 - (F) Tumor necrosis factor α
96. During a study of renal glomeruli, a healthy animal kidney is kept in a vascular bath preparation at a constant afferent arterial pressure of 100 mm Hg. If the efferent arteriole is constricted with a vascular clamp, which of the following Starling forces is most likely to change in the glomeruli?
- (A) Decreased filtration coefficient (K_f)
 - (B) Decreased hydrostatic pressure
 - (C) Decreased oncotic pressure
 - (D) Increased hydrostatic pressure
 - (E) Increased oncotic pressure

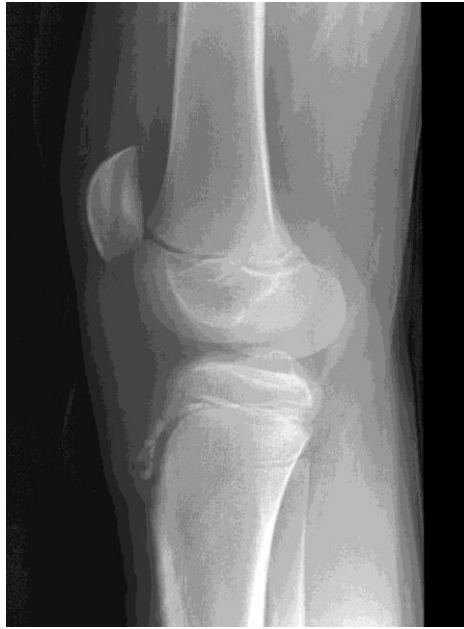97. A 67-year-old woman is brought to the emergency department 30 minutes after she had a generalized tonic-clonic seizure. Her family says that she seemed mildly confused before her eyes rolled backward and she had the onset of uncontrollable jerking movements of her arms and legs and loss of consciousness. During the seizure, she passed urine and bit her tongue. At the scene, her vital signs were within normal limits. She has a 6-month history of a 7-kg (15-lb) weight loss despite no changes in appetite. She received the diagnosis of small cell carcinoma of the lung last week and has not begun treatment. She has hypertension well controlled with lisinopril. On arrival, she is awake but does not respond to verbal stimuli. She is not in distress. Her temperature is 37°C (98.6°F), pulse is 70/min, and blood pressure is 130/88 mm Hg while supine. Examination shows no abnormalities. Laboratory studies show:

| | |
|-------------------------------|--------------------------------|
| Serum | |
| Na ⁺ | 115 mEq/L |
| K ⁺ | 4 mEq/L |
| Cl ⁻ | 81 mEq/L |
| HCO ₃ ⁻ | 25 mEq/L |
| Urea nitrogen | 9 mg/dL |
| Glucose | 102 mg/dL |
| Creatinine | 0.6 mg/dL |
| Urine | |
| Sodium | 60 mEq/L |
| Potassium | 20 mEq/L |
| Osmolality | 900 mOsmol/kg H ₂ O |

Which of the following is the most likely diagnosis?

- (A) Adrenal insufficiency
(B) Diuretic abuse
(C) Heart failure
(D) Syndrome of inappropriate secretion of ADH (vasopressin)
(E) Water intoxication
-
98. A 23-year-old woman comes to the physician for genetic counseling prior to conception. Her brother and maternal uncle had Duchenne muscular dystrophy (DMD) and died at the ages of 28 and 17 years, respectively. Genetic analysis was not performed on either relative prior to death. Serum studies show a muscle creatine kinase concentration of 120 U/L (N=22–198). The patient's 50-year-old mother has a serum muscle creatine kinase concentration of 300 U/L. Which of the following is the most appropriate assessment of this patient's carrier status for this disease?
- (A) The patient has a 50% risk for developing DMD
(B) The patient has a 50% risk of having a child with DMD
(C) The patient is a carrier of the disease based on her family history of DMD
(D) The patient is not a carrier of the DMD based on her normal creatine kinase concentration
(E) The patient's DMD carrier status is uncertain because of random X inactivation
99. A randomized controlled trial is conducted to assess the risk for development of gastrointestinal adverse effects using azithromycin compared with erythromycin in the treatment of pertussis in children. Of the 100 children with pertussis enrolled, 50 receive azithromycin, and 50 receive erythromycin. Results show vomiting among 5 patients in the azithromycin group, compared with 15 patients in the erythromycin group. Which of the following best represents the absolute risk reduction for vomiting among patients in the azithromycin group?
- (A) 0.1
(B) 0.2
(C) 0.33
(D) 0.67
(E) 0.8

100. A 35-year-old woman comes to the office because of a 3-day history of severe right back pain. She has not had any fever, chills, or weight loss. She has no history of major medical illness. Musculoskeletal and neurologic examinations show no abnormalities. When told that her examination is normal, the patient becomes tearful and demands an MRI of her back because her mother just died from breast cancer metastatic to bone and she fears that she may also have cancer. The patient already contacted her insurance company, who told her that if she has neurologic abnormalities an MRI may be covered by her plan. The patient asks the physician to order the MRI indicating that she has neurologic findings. Which of the following is the most appropriate initial action by the physician?
- (A) Advise the patient to change insurance companies as soon as she is able so that she can receive more comprehensive medical care
 - (B) Explain that the patient does not need the MRI and that it is not appropriate to misrepresent her examination findings
 - (C) Immediately inform the patient's insurance company about what the patient has asked the physician to do
 - (D) Order the MRI as the patient requests
 - (E) Recommend that the patient pay for the MRI out-of-pocket in order to ease her worry
101. A 6-day-old breast-fed boy is brought to the emergency department by his mother because of poor weight gain and irritability since delivery, and a 2-hour history of vomiting. Physical examination shows jaundice and hepatomegaly. A reducing substance test result of the urine is positive, and a glucose oxidase test result is negative. The concentration of which of the following metabolites in liver is most likely increased in this patient?
- (A) Fructose 1,6-bisphosphate
 - (B) Galactose 1-phosphate
 - (C) Glucose 1-phosphate
 - (D) Glucose 6-phosphate
102. A 14-year-old boy is brought to the physician because of a 2-day history of a sore throat and fever that peaks in the late afternoon. He also has a 1-week history of progressive fatigue. He recently began having unprotected sexual intercourse with one partner. He appears ill. His temperature is 39°C (102.2°F). Physical examination shows cervical lymphadenopathy and pharyngeal erythema with a creamy exudate. Which of the following is the most likely diagnosis?
- (A) Candidiasis
 - (B) Herpangina
 - (C) Infectious mononucleosis
 - (D) Mumps
 - (E) Syphilis
103. In a cohort study of elderly women, the relative risk ratio for hip fractures among those who exercise regularly is 1.2 (95% confidence interval of 1.1 to 1.8). Which of the following is the most appropriate conclusion about the effect of regular exercise on the risk for hip fracture?
- (A) Statistically nonsignificant increase in risk
 - (B) Statistically nonsignificant overall decrease in risk
 - (C) Statistically significant overall decrease in risk
 - (D) Statistically significant overall increase in risk



104. A 12-year-old boy is brought to the physician by his mother because of a 1-month history of pain below the left knee. His mother says, "He can usually walk around, but he hasn't been able to play in any of his soccer games since this all began." Examination of the left knee shows warmth, swelling, and tenderness. An x-ray of the knee is shown. Which of the following structures is attached to the abnormal anterior tibial area?
- (A) Anterior cruciate ligament
 - (B) Gastrocnemius muscle
 - (C) Patellar ligament
 - (D) Popliteus muscle
 - (E) Posterior cruciate ligament
 - (F) Soleus muscle
-
105. A 22-year-old woman comes to the office because of a 3-day history of cold symptoms and a 1-week history of progressive fatigue. Six weeks ago, she received a kidney transplant from a living, related donor. Immediately after the operation, she received monoclonal anti-CD3 therapy. Current medications are azathioprine, cyclosporine, and prednisone. Her temperature is 39°C (102.2°F). Physical examination shows a well-healed surgical scar. Serum studies show that her urea nitrogen and creatinine concentrations have tripled. A diagnosis of allograft rejection is suspected. In addition, this patient's clinical presentation is best explained by an infection with which of the following agents?
- (A) Adenovirus
 - (B) BK virus
 - (C) Epstein-Barr virus
 - (D) Herpes simplex virus
 - (E) Varicella-zoster virus

106. A new test to detect the presence of malarial antibodies by ELISA is evaluated in 100 patients with active untreated malaria proven by demonstration of blood-borne parasites and in 100 patients with no history of infection. Results of testing are shown:

| ELISA Test Results | | Malaria | | |
|----------------------|--|---------|--------|-----|
| | | Present | Absent | |
| Positive Negative | | 75 | 5 | 80 |
| | | 25 | 95 | 120 |
| | | 100 | 100 | 200 |

Which of the following is the specificity of this test?

- (A) 65%
- (B) 71%
- (C) 75%
- (D) 94%
- (E) 95%

107. A 30-year-old woman comes to the physician because of a 2-day history of abdominal pain. She has a history of recurrent upper respiratory tract infections, sinusitis, and pancreatitis. She has thick nasal secretions. She says that her sweat is salty and crystallizes on her skin. Her vital signs are within normal limits. Physical examination shows epigastric tenderness. Genetic testing for the 36 most common mutations shows a detectable mutation (G551D) in one allele of the *CFTR* gene. Which of the following best explains this patient's clinical phenotype?

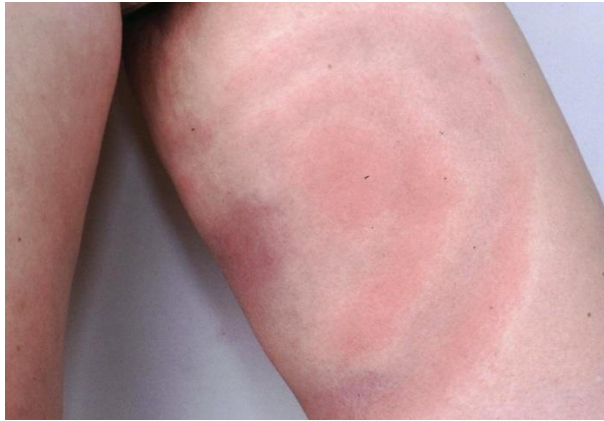- (A) Loss of heterozygosity of the *CFTR* gene has occurred in the pancreas
- (B) Only one G551D allele is needed in *CFTR*
- (C) The patient is a *CFTR* obligate carrier
- (D) The patient's *CFTR* mutation is unrelated to her clinical phenotype
- (E) The second *CFTR* mutation was not detected by the testing obtained

108. A 52-year-old man is brought to the emergency department 30 minutes after he had an episode of chest pain radiating to his jaw while shoveling snow. His pulse is 80/min, and blood pressure is 130/70 mm Hg. The lungs are clear to auscultation. Cardiac examination shows an S_4 . While undergoing an ECG, the patient says that he feels the chest pain returning. The most appropriate immediate treatment is a drug with which of the following mechanisms of action?

- (A) Increases cAMP concentration
- (B) Increases nitric oxide concentration
- (C) Inhibits potassium flux
- (D) Inhibits sodium flux

109. A technician wants to determine whether cytomegalovirus (CMV) DNA is present in the blood of a bone marrow transplant recipient. DNA purified from the leukocytes of the patient is reacted in a mixture containing oligonucleotides specific for CMV DNA, thermostable DNA polymerase, and nucleotides. Repetitive cycles of heating and cooling are performed, and the reaction product is detected by gel electrophoresis. The technician most likely used which of the following laboratory procedures on this patient's blood?

- (A) Northern blotting
- (B) Polymerase chain reaction
- (C) Reverse transcription
- (D) Southern blotting
- (E) Western blotting



110. A 16-year-old boy comes to the physician because of a rash on his left inner thigh that first appeared 2 days after he returned from a hunting trip with friends in Minnesota. A photograph of the rash is shown. Without treatment, this patient is at increased risk for which of the following?
- (A) Carditis
 - (B) Glomerulonephritis
 - (C) Hepatitis
 - (D) Pancreatitis
 - (E) Thrombocytopenia
-
111. After being severely beaten and sustaining a gunshot wound to the abdomen, a 42-year-old woman undergoes resection of a perforated small bowel. During the operation, plastic reconstruction of facial fractures, and open reduction and internal fixation of the left femur are also done. Thirty-six hours postoperatively, she is awake but not completely alert. She is receiving intravenous morphine via a patient-controlled pump. She says that she needs the morphine to treat her pain, but she is worried that she is becoming addicted. She has no history of substance use disorder. She drinks one to two glasses of wine weekly. Which of the following initial actions by the physician is most appropriate?
- (A) Reassure the patient that her chance of becoming addicted to narcotics is minuscule
 - (B) Maintain the morphine, but periodically administer intravenous naloxone
 - (C) Switch the patient to oral acetaminophen as soon as she can take medication orally
 - (D) Switch the patient to intramuscular lorazepam
 - (E) Switch the patient to intravenous phenobarbital
112. A 51-year-old man comes to the office because of a 6-month history of a lump on his tongue that is interfering with his speech and eating; he also has had a 6.8-kg (15-lb) weight loss during this period. He has smoked 1 pack of cigarettes daily and has consumed six 12-oz bottles of beer on weekend nights during the past 30 years. His vital signs are within normal limits. Physical examination shows a 1.5-cm mass on the apex of the tongue. Further evaluation of the mass confirms squamous cell carcinoma. It is most appropriate to evaluate which of the following lymph nodes first for evidence of metastasis in this patient?
- (A) Inferior deep cervical
 - (B) Parotid
 - (C) Retropharyngeal
 - (D) Submental
 - (E) Superior deep cervical

113. A 31-year-old woman comes to the physician because of a 2-week history of malaise, nausea, vomiting, and decreased appetite. She is a known user of intravenous heroin. She appears chronically ill. She is 165 cm (5 ft 5 in) tall and weighs 47 kg (103 lb); BMI is 17 kg/m². Her temperature is 36.7°C (98.1°F), pulse is 90/min, respirations are 18/min, and blood pressure is 114/68 mm Hg. Physical examination shows scleral icterus and a liver span of 16 cm. The spleen is not palpable. Serum studies show:

| | |
|--------------------------------|-----------|
| Total bilirubin | 3.2 mg/dL |
| AST | 774 U/L |
| ALT | 820 U/L |
| HIV antibody | negative |
| Hepatitis B surface antigen | negative |
| Hepatitis B surface antibody | positive |
| Anti-hepatitis B core antibody | positive |
| Hepatitis B DNA | negative |
| Anti-hepatitis C virus | positive |
| Hepatitis C RNA | positive |

Which of the following is the most likely outcome of this patient's infection?

- (A) Complete resolution of infection
 - (B) Latent infection with intermittent viremia
 - (C) Lifelong persistent infection
 - (D) Patient death from acute infection
-

114. A 57-year-old man receives radiation therapy for a squamous cell carcinoma of the lung. Despite therapy, the tumor progressively increases in size, and he dies 6 months later. His tumor cells contain a point mutation in the p53 gene (*TP53*), leading to an inactive gene product. Based on this finding, the progressive tumor growth despite irradiation therapy is most likely to be related to a defect in cell cycle arrest in which of the following phases of the cell cycle?

- (A) G₀
- (B) G₁
- (C) G₂
- (D) M
- (E) S

115. A 55-year-old man comes to the physician for a routine physical examination. He is currently taking no medications. His pulse is 80/min, and blood pressure is 165/95 mm Hg. Physical examination shows no other abnormalities. The presence of which of the following mechanisms is most likely to increase this patient's blood pressure further?

- (A) Decreased cardiac output
- (B) Decreased pulse
- (C) Decreased stroke volume
- (D) Increased peripheral vascular resistance
- (E) Increased pulmonary artery pressure

116. A 53-year-old man comes to the physician because of a 6-month history of intermittent blood in his stool. He has had no pain with defecation. Physical examination shows a 1-cm, visible anal mass located below the dentate line. A biopsy of the mass is scheduled. If the mass is found to be malignant, it is most appropriate to evaluate which of the following lymph nodes for possible metastasis?
- (A) Internal iliac
 - (B) Popliteal
 - (C) Sacral
 - (D) Superficial inguinal
 - (E) Superior rectal
117. A 59-year-old man is brought to the emergency department because of a 4-day history of nausea, vomiting, and diarrhea. He also has been confused and agitated during this period. He has a history of mild hypertension. His current medication is a diuretic. His temperature is 37°C (98.6°F), pulse is 108/min, respirations are 26/min, and blood pressure is 70/47 mm Hg. Physical examination shows delayed capillary refill of the lips and nail beds and cool extremities. His oxyhemoglobin saturation in a central vein is 60% (N=70–75). These findings are most consistent with which of the following types of shock?
- (A) Cardiogenic
 - (B) Distributive
 - (C) Hypovolemic
 - (D) Obstructive
 - (E) Septic

ANSWER FORM FOR USMLE STEP 1 SAMPLE TEST QUESTIONS

Block 1 (Questions 1–40)

| | | | | | | | |
|-----|-----|-----|-----|-----|-----|-----|-----|
| 1. | ___ | 11. | ___ | 21. | ___ | 31. | ___ |
| 2. | ___ | 12. | ___ | 22. | ___ | 32. | ___ |
| 3. | ___ | 13. | ___ | 23. | ___ | 33. | ___ |
| 4. | ___ | 14. | ___ | 24. | ___ | 34. | ___ |
| 5. | ___ | 15. | ___ | 25. | ___ | 35. | ___ |
| 6. | ___ | 16. | ___ | 26. | ___ | 36. | ___ |
| 7. | ___ | 17. | ___ | 27. | ___ | 37. | ___ |
| 8. | ___ | 18. | ___ | 28. | ___ | 38. | ___ |
| 9. | ___ | 19. | ___ | 29. | ___ | 39. | ___ |
| 10. | ___ | 20. | ___ | 30. | ___ | 40. | ___ |

Block 2 (Questions 41–80)

| | | | | | | | |
|-----|-----|-----|-----|-----|-----|-----|-----|
| 41. | ___ | 51. | ___ | 61. | ___ | 71. | ___ |
| 42. | ___ | 52. | ___ | 62. | ___ | 72. | ___ |
| 43. | ___ | 53. | ___ | 63. | ___ | 73. | ___ |
| 44. | ___ | 54. | ___ | 64. | ___ | 74. | ___ |
| 45. | ___ | 55. | ___ | 65. | ___ | 75. | ___ |
| 46. | ___ | 56. | ___ | 66. | ___ | 76. | ___ |
| 47. | ___ | 57. | ___ | 67. | ___ | 77. | ___ |
| 48. | ___ | 58. | ___ | 68. | ___ | 78. | ___ |
| 49. | ___ | 59. | ___ | 69. | ___ | 79. | ___ |
| 50. | ___ | 60. | ___ | 70. | ___ | 80. | ___ |

Block 3 (Questions 81–117)

| | | | | | | | |
|-----|-----|------|-----|------|-----|------|-----|
| 81. | ___ | 91. | ___ | 101. | ___ | 111. | ___ |
| 82. | ___ | 92. | ___ | 102. | ___ | 112. | ___ |
| 83. | ___ | 93. | ___ | 103. | ___ | 113. | ___ |
| 84. | ___ | 94. | ___ | 104. | ___ | 114. | ___ |
| 85. | ___ | 95. | ___ | 105. | ___ | 115. | ___ |
| 86. | ___ | 96. | ___ | 106. | ___ | 116. | ___ |
| 87. | ___ | 97. | ___ | 107. | ___ | 117. | ___ |
| 88. | ___ | 98. | ___ | 108. | ___ | | |
| 89. | ___ | 99. | ___ | 109. | ___ | | |
| 90. | ___ | 100. | ___ | 110. | ___ | | |

ANSWER KEY FOR USMLE STEP 1 SAMPLE TEST QUESTIONS

Block 1 (Questions 1–40)

| | | | |
|-------|-------|-------|-------|
| 1. D | 11. D | 21. B | 31. A |
| 2. A | 12. E | 22. E | 32. E |
| 3. D | 13. C | 23. A | 33. E |
| 4. A | 14. D | 24. A | 34. E |
| 5. E | 15. C | 25. A | 35. D |
| 6. C | 16. A | 26. B | 36. D |
| 7. C | 17. D | 27. C | 37. C |
| 8. B | 18. B | 28. C | 38. C |
| 9. C | 19. B | 29. B | 39. A |
| 10. F | 20. B | 30. C | 40. B |

Block 2 (Questions 41–80)

| | | | |
|-------|-------|-------|-------|
| 41. C | 51. C | 61. A | 71. B |
| 42. E | 52. G | 62. A | 72. C |
| 43. D | 53. C | 63. C | 73. A |
| 44. A | 54. B | 64. C | 74. A |
| 45. B | 55. D | 65. B | 75. A |
| 46. A | 56. E | 66. A | 76. A |
| 47. C | 57. E | 67. B | 77. D |
| 48. E | 58. D | 68. E | 78. B |
| 49. D | 59. E | 69. E | 79. E |
| 50. D | 60. A | 70. A | 80. E |

Block 3 (Questions 81–117)

| | | | |
|-------|--------|--------|--------|
| 81. A | 91. C | 101. B | 111. A |
| 82. E | 92. C | 102. C | 112. D |
| 83. E | 93. B | 103. D | 113. C |
| 84. E | 94. A | 104. C | 114. B |
| 85. E | 95. F | 105. B | 115. D |
| 86. A | 96. D | 106. E | 116. D |
| 87. B | 97. D | 107. E | 117. C |
| 88. B | 98. E | 108. B | |
| 89. C | 99. B | 109. B | |
| 90. E | 100. B | 110. A | |